

Lyme Carditis: Where Is the Site of the Atrioventricular Block?

A 23-year-old man presented to an outside hospital with the chief complaint of fatigue and dizzy spells. He was diagnosed with Lyme disease based on the history of a tick bite, the presence of erythema migrans (2 months after the tick bite), and Borrelia IgG and IgM antibodies demonstrated by enzyme-linked immunosorbent assay and western blot findings. The patient specifically denied any history of syncope; however, the conduction system pacing was recommended due to recurrent dizzy spells. After the first electrocardiography (ECG) was taken at admission (Figure 1A and 1B), we decided to perform atropine testing (Figure 1C and 1D). Where do you locate the site of the block in the ECG?

Lyme disease is the most common tick-borne disease in the United States and Europe the duration of infection and the species of Lyme borrelia causing the infection can affect the clinical features of Lyme disease. The 2:1 AV block may be atrioventricular (AV) nodal, intrahisian, infrahisian, or at multiple levels.

We had a 2:1 second-degree AV block in which the conducted beats show a narrow QRS complex. Indeed, a 2:1 AV block may be atrioventricular (AV) nodal, intrahisian, infrahisian, or at multiple levels,¹⁻⁵ and it might be difficult to differentiate these only from the surface ECG.¹ It cannot be easy also to rule out the blocked atrial bigeminy. Note that during the 2:1 AV block there was a ventriculophasic sinus arrhythmia. The PP intervals containing a QRS in between were shorter than those not including a ventricular depolarization (Figure 1B). However, every blocked P wave was a sinus P wave (morphology), since both were identical to sinus ones (Figure 1B), and we rule out the blocked atrial bigeminy.

When the QRS is normal, the level of the block is either AV node or intrahisian. When the QRS is wide, all 3 options are on the table. Therefore, the narrow QRS complexes easily exclude the bundle branches as the site of the AV block. In addition, measuring the PR interval of the conducted P wave in the 2:1 block can be of help.⁶ In the presence of the narrow QRS and 2:1 block, the normal PR interval suggest the intrahisian block, whereas the presence of the prolonged PR of the conducted beat proposes that the block is generally in the AV node. Furthermore, even when there was sinus tachycardia (Figure 1C) at the time he was having PR prolongation. Therefore, we performed the atropine testing (Figure 1D), which result in a 2:1 AV block. Atropine and exercise will improve AV nodal conduction.⁷ Therefore, if the conduction improves with atropine or exercise, or worsens with CSM, the block is in the AV node.^{6,8} If the conduction worsens with atropine or exercise or improves with CSM, the block is in His or bundle branches.⁸ It looks like a discrepancy at the first stage, whereas the PR prolongation suggests the AV nodal block; the atropine testing proposed the intrahisian block. Then the patient further underwent an electrophysiology study for evaluation of conduction system disease. The split His signals were seen on electrograms (Figure 2A) as a sign of the typical intra-His block because the QRS was normal and this was a rare finding to see on one catheter a split His. A split His bundle signal spanning more than 30 milliseconds or a block occurring between these split signals, as in this case, seals the diagnosis of intrahisian block.¹ Typically in the infra-nodal block, the PR interval is not prolonged; however, that is frequently the case in 2:1 AV nodal block.⁶ Two levels of the block, which can be either in the AV node, the AV node, and HPS

E-PAGE ORIGINAL IMAGE

Gamze Aktaş¹ 

Mustafa Yenerçağ² 

Ezgi Merve Çelik¹ 

İrem Ünal¹ 

Ahmet Korkmaz¹ 

Fırat Özcan¹ 

Serkan Çay¹ 

Özcan Özeke¹ 

Dursun Aras³ 

Serkan Topaloğlu¹ 

¹Department of Cardiology, University of Health Sciences, Ankara City Hospital, Ankara, Türkiye

²Department of Cardiology, Samsun University Training and Research Hospital, Samsun, Türkiye

³Department of Cardiology, İstanbul Medipol University, İstanbul, Türkiye

Corresponding author:

Özcan Özeke

✉ ozcanozeke@gmail.com

Cite this article as: Aktaş G, Yenerçağ M, Çelik EM, et al. Lyme carditis: Where is the site of the atrioventricular block? *Anatol J Cardiol.* 2024;28(5):E-19-E-21.

DOI:10.14744/AnatolJCardiol.2024.4266



Copyright©Author(s) - Available online at anatoljcardiol.com.
Content of this journal is licensed under a Creative Commons Attribution-NonCommercial 4.0 International License.

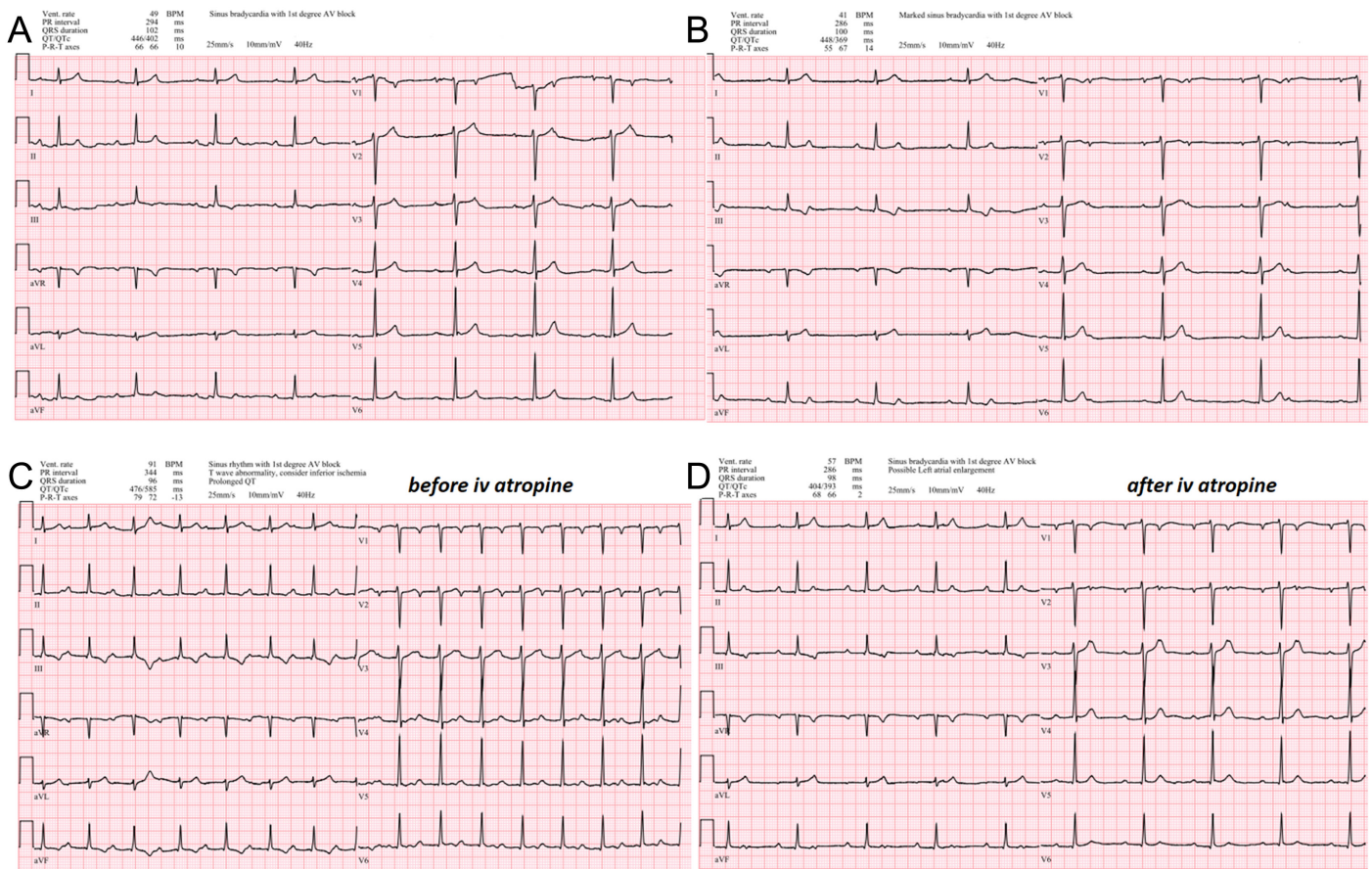


Figure 1. (A and B) Electrocardiogram at taken on admission. (C and D) Response to atropine test.

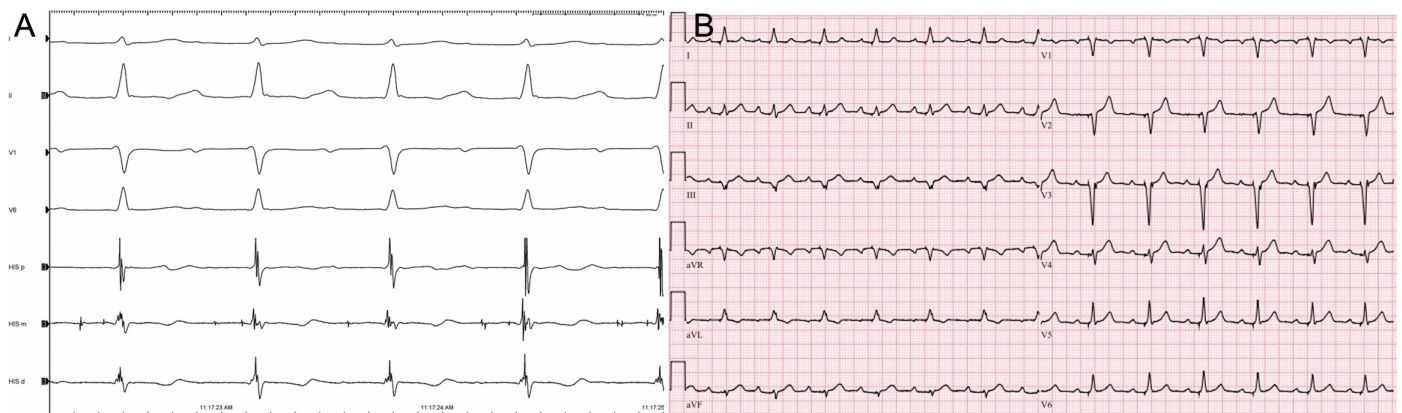


Figure 2. (A) Electrograms during electrophysiological study. (B) Electrocardiogram following the conduction system pacing.

or 2 levels in the HPS, might be responsible in that situation. The presence of an AV block with irregular RR intervals with a pattern not fitting into a simple type 1 block should suggest the presence of a multilevel block. Lyme disease is the most common tick-borne disease in the United States and Europe.⁹ The duration of infection and the species of Lyme borrelia causing the infection can affect the clinical features of Lyme disease.⁹ The patient underwent temporary–permanent left bundle branch area and right atrial pacing with concomitant long-term ceftriaxone therapy (Figure 2B). One year later after long-term ceftriaxone therapy without

symptomatology and pacemaker dependency, early pacemaker explantation performed.

Informed Consent: Written informed consent was obtained from the patient.

Declaration of Interests: The authors have no conflict of interest to declare.

Funding: The authors declare that this study received no financial support.

REFERENCES

1. Bansal R, Rathi C, Lokhandwala Y. Where is the level of atrioventricular block? *Circulation*. 2020;142(17):1684-1686. [\[CrossRef\]](#)
2. Kanal Y, Yıldız CE, Ayhan G, Yakut İ, Özeke Ö. High-degree atrioventricular heart block induced by pramipexole. *Anatol J Cardiol*. 2022;26(2):147-148. [\[CrossRef\]](#)
3. Ekizler FA, Sahin M, Ozeke O, et al. Atrial pacing-induced paroxysmal atrioventricular block: concealed conduction or phase 3 block or intrahisian reentry? *Pacing Clin Electrophysiol*. 2019;42(8):1165-1166. [\[CrossRef\]](#)
4. Celik IE, Akyel A, Colgecen M, Ozeke O. A rare cause of 2:1 atrioventricular block: carbamazepine. *Am J Emerg Med*. 2015;33(10):1541.e3-1541.e4. [\[CrossRef\]](#)
5. Sensoy B, Ozeke O, Canpolat U, et al. Phase-4 paroxysmal atrioventricular block in sarcoidosis. *Herz*. 2015;40(2):321-324. [\[CrossRef\]](#)
6. Josephson ME, Wellens HJ. Episodic dizziness in a 74-year-old woman. *Heart Rhythm*. 2014;11(12):2329-2330. [\[CrossRef\]](#)
7. Varma N. Right bundle branch block and second-degree atrioventricular block: what is the mechanism? *Heart Rhythm*. 2005;2(3):325-327. [\[CrossRef\]](#)
8. Katritsis DG, Josephson ME. Electrophysiological testing for the investigation of bradycardias. *Arrhythm Electrophysiol Rev*. 2017;6(1):24-28. [\[CrossRef\]](#)
9. Marques AR, Strle F, Wormser GP. Comparison of Lyme disease in the United States and Europe. *Emerg Infect Dis*. 2021;27(8):2017-2024. [\[CrossRef\]](#)