

Successful management of a rare and fatal complication of cardiac catheterization: Abdominal compartment syndrome

İsmail Balaban, Berhan Keskin, Ahmet Karaduman, Ali Karagöz, Regayip Zehir
 Department of Cardiology, Health Sciences University Koşuyolu Heart Training and Research Hospital; İstanbul-Turkey

Introduction

Retroperitoneal hematoma (RPH) is a potentially fatal complication of coronary angiography. The prevalence of RPH after cardiac catheterization is 0.04%–0.74% (1). RPHs may result in abdominal pain, femoral neuropathy, need for transfusion, abdominal compartment syndrome (ACoS), acute kidney injury, and death. ACoS is consistent with intraabdominal pressure >25 mm Hg and is surgically treated (2). Occurrence of ACoS after coronary angiography is a rare incident, and clinicians should suspect ACoS in the presence of clinical clues.

Case Report

A 55-year-old male patient applied to the emergency service with abdominal pain, dyspnea, and feeling of weakness. He had undergone diagnostic coronary angiography 1 week ago. Aortic and mitral valve replacement had been performed for him 7 years ago, and he was on warfarin. On physical examination, he looked pale, and tenderness and rigidity were observed in the right lower abdomen. His blood pressure was 81/56 mm Hg, pulse rate was 121 bpm, and Spo2 was 95%. Significant anemia [Hemoglobin (Hb): 6.9 g/dL] and prolonged INR (5.1) were observed, and his kidney function test results were as follows: serum creatinine, 1.9 and urea, 79 mg/dL. One week ago, before discharge from the hospital, his Hb level was 11.6 g/dL and creatinine level was 0.6 mg/dL. Because of high clinical suspicion of RPH, abdominal computed tomography (CT) was performed. Fluid resuscitation was started, and abdominal CT images were obtained. Abdominal CT images revealed an RPH (Fig. 1a, 1b). We proceeded with invasive imaging because of persistent clinical instability, hypotension, and developing anemia despite supportive treatment interventions such as fluid infusion and fresh frozen plasma and blood transfusions. Extravasation from the femoral artery was observed on conventional angiography (Fig. 1c, Video 1). A 6.0×57 mm covered Advanta V12 stent-graft (Atrium, Hudson, NH, USA) was implanted inside the femoral artery, following which the extravasation disappeared (Fig. 1d, Video 2). Then the patient was transferred to the intensive care unit. During follow-up, oliguria was detected and intraabdominal pressure was measured to be 16 mm Hg using an intravesical catheter. Continuation of close

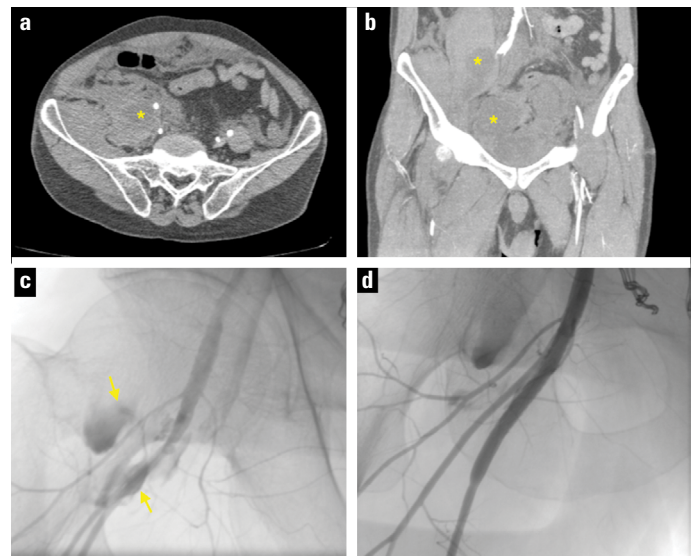


Figure 1. (a, b) Retroperitoneal hematoma observed on axial and coronal abdomen computed tomography images (c) Extravasation of contrast medium from the femoral artery on the angiographic image (d) Disappearance of the extravasation after graft-stent placement inside the femoral artery

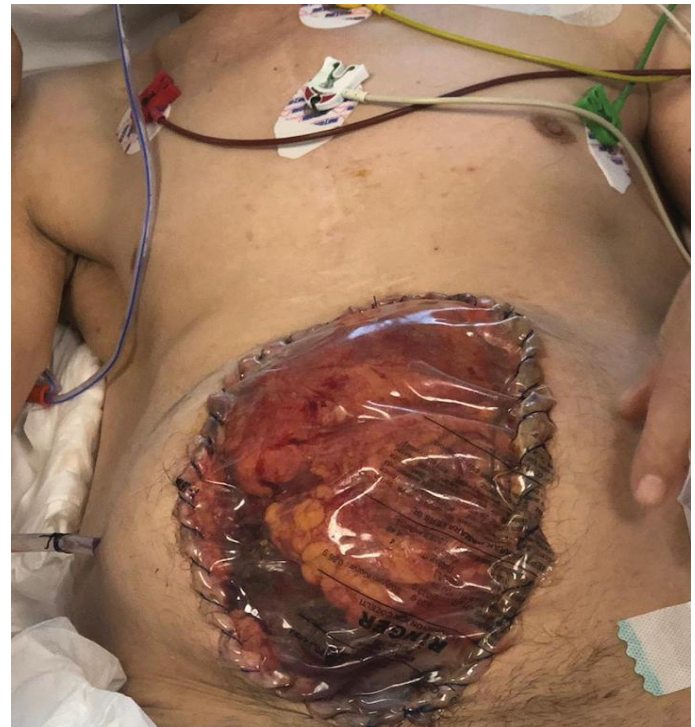


Figure 2. Appearance of the abdomen after surgical decompression

follow-up was advised after gastroenterology–surgery consultation. Six hours later, anuria developed, and intravesical measurement of intraabdominal pressure showed a value of 26 mm Hg; thus, ACoS diagnosis was confirmed. The patient underwent surgical decompression (Fig. 2), following which urine output was restored and renal function tests returned to normal values in 2 days. The Hb level was normalized in the following days. Patient's skin was closed 4 days postoperatively. Anticoagulation

was started 1 day postoperatively. He was discharged from the hospital 10 days after surgical decompression.

Discussion

RPH is a rare complication after cardiac catheterization (1). Clinicians should suspect RPH in the presence of related symptoms such as abdominal pain and signs of blood loss after a predisposing condition such as cardiac catheterization. RPH can be managed conservatively, percutaneously, or surgically (3). In cases where hemodynamic conditions are unstable, an early invasive approach may be considered to prevent further deterioration (4). Tachycardia, hypotension, significant anemia, and signs of hypovolemic shock may be alarming for the clinician.

ACoS can be caused by retroperitoneal bleeding with increasing intraabdominal pressure. Clinicians should closely monitor abdominal hypertension so as not to miss ACoS. Some factors such as warfarin use and ascites may act as triggers for the ACoS development (5). Acute renal failure is common in patients with ACoS; other intraabdominal organs may also be affected. Intraabdominal pressure increase leads to elevated intrathoracic pressure. Increasing lactate levels, metabolic acidosis, and increased intrathoracic pressure negatively affect cardiovascular performance by depressing myocardium and vasodilatation. Close monitoring for the development of ACoS is possible using various methods. Intravesical measurement of intraabdominal pressure is an indirect and noninvasive gold standard method (2). In the presence of objective evidence for ACoS, surgical decompression is the preferred treatment method (6). In our patient, we used a percutaneous approach for an unstable hemodynamic condition caused by retroperitoneal bleeding and performed surgical decompression for ACoS that had developed during follow-up. It is essential to increase awareness about the diagnostic and therapeutic approaches to this rare clinical condition. Furthermore, radial approach may be more suitable in patients who are prone to bleeding, such as our patient who was on anticoagulation because of the placement of mechanical prosthetic valves (7).

Conclusion

Occurrence of RPH after interventional procedures to the femoral artery is uncommon, and RPH can be complicated by ACoS. The affected patients can present with an unstable clinical condition; thus, suspecting the presence of ACoS is essential to manage critical patients. Close follow-up in RPH patients is advisable to recognize ACoS earlier to prevent further end-organ damage with appropriate treatment.

Informed consent: Informed consent was obtained from the patient and his relatives for publishing this case report.

Video 1. Extravasation of contrast medium from the femoral artery on angiography

Video 2. Disappearance of extravasation after graft-stent placement inside the femoral artery

References

1. Trimarchi S, Smith DE, Share D, Jani SM, O'Donnell M, McNamara R, et al. Retroperitoneal hematoma after percutaneous coronary intervention: prevalence, risk factors, management, outcomes, and predictors of mortality: a report from the BMC2 (Blue Cross Blue Shield of Michigan Cardiovascular Consortium) registry. *JACC Cardiovasc Interv* 2010; 3: 845-50. [CrossRef]
2. Maluso P, Olson J, Sarani B. Abdominal Compartment Hypertension and Abdominal Compartment Syndrome. *Crit Care Clin* 2016; 32: 213-22. [CrossRef]
3. Eisen A, Kornowski R, Vaduganathan M, Lev E, Vaknin-Assa H, Bental T, et al. Retroperitoneal bleeding after cardiac catheterization: a 7-year descriptive single-center experience. *Cardiology* 2013; 125: 217-22. [CrossRef]
4. Seropian IM, Angiolillo DJ, Zenni MM, Bass TA, Guzman LA. Should endovascular approach be the first line of treatment for retroperitoneal bleeding with hemodynamic shock following percutaneous intervention? A case series. *Catheter Cardiovasc Interv* 2017; 90: 104-11. [CrossRef]
5. Patel DM, Connor MJ Jr. Intra-Abdominal Hypertension and Abdominal Compartment Syndrome: An Underappreciated Cause of Acute Kidney Injury. *Adv Chronic Kidney Dis* 2016; 23: 160-6.
6. Sosa G, Gandham N, Landeras V, Calimag AP, Lerma E. Abdominal compartment syndrome. *Dis Mon* 2019; 65: 5-19. [CrossRef]
7. Nardin M, Verdoia M, Barbieri L, Schaffer A, Suryapranata H, De Luca G. Radial vs Femoral Approach in Acute Coronary Syndromes: A Meta-Analysis of Randomized Trials. *Curr Vasc Pharmacol* 2017; 16: 79-92. [CrossRef]

Address for Correspondence: Dr. İsmail Balaban,

Sağlık Bilimleri Üniversitesi Koşuyolu

Eğitim ve Araştırma Hastanesi,

Kardiyoloji Kliniği,

İstanbul-Türkiye

Phone: +90 507 931 50 31

E-mail: ismailbalabanmd@gmail.com

©Copyright 2020 by Turkish Society of Cardiology - Available online

at www.anatoljcardiol.com

DOI:10.14744/AnatolJCardiol.2019.96049



Percutaneous closure of a secundum atrial septal defect through femoral approach in an adult patient with interrupted inferior vena cava and azygos continuation

İ Elnur Alizade, İ Ahmet Karaduman, İ İsmail Balaban,

İ Berhan Keskin, İ Semih Kalkan

Department of Cardiology, Koşuyolu Heart Training and Research Hospital; Istanbul-Turkey

Introduction

Percutaneous closure of an isolated secundum atrial septal defect (ASD) has become the first-line treatment in patients with