

## The imaging of the aortic fibrous membrane associated with Williams syndrome

### Williams sendromu ile ilişkili aortik fibroz membran görüntüsü

Williams syndrome (WS) is a rare multisystemic disorder caused by a microdeletion of chromosome 7 and is associated with dysmorphic facial features, supraaortic stenosis (SVS) and other cardiovascular diseases, mental retardation, infantile hypercalcemia, and growth deficiency. The most significant medical problem associated with this syndrome is cardiovascular disease caused by narrowed arteries. Because of the variability in the way that WS affects different people, it often goes undiagnosed for many years. Clinical suspicion is essential because the diagnostic genetic finding is not detectable on routine chromosomal analysis and is not cost effective to screen all patients. We present the nicely transthoracic echocardiographic and angiographic images of the SVS caused by discrete fibrous membrane in a young patient with WS.

A 20-year-old woman was admitted for evaluation of her cardiac murmur. She was short in stature, had a characteristic face of WS and moderate mental retardation, whereas she was talkative and gregarious. On auscultation, a harsh systolic murmur that radiated to the bilateral neck vessels on the second sternal border was audible. The electrocardiogram revealed left ventricular hypertrophy, and chest radiography showed no abnormality. The transthoracic echocardiography detected no aortic valve or left ventricular outflow tract obstruction, however, there was 143 mmHg pressure gradient at the aortic level with Doppler echocardiography (Fig. 1A). On the suprasternal echocardiographic view (Fig 1A) and the aortogram (Fig. 1B and 1C, Video 1. See corresponding video/movie images at [www.anakarder.com](http://www.anakarder.com)), a discrete fibrous membrane above sinuses of Valsalva was seen. The discrete fibrous membrane was confirmed at surgery, and aortoplasty for supraaortic stenosis was performed successfully.

Hacı Çiftçi, Özcan Özeke<sup>1</sup>, Fikri Kutlay\*, Uğur Yuvaçç<sup>2</sup>  
From Departments of Cardiology and \*Cardiovascular Surgery,  
Veni Vidi Hospital; <sup>1</sup>Department of Cardiology, Diyarbakır Military  
Hospital; <sup>2</sup>Department of Cardiology, Güneyođu Hospital,  
Diyarbakır, Turkey

Address for Correspondence/Yazışma Adresi: Özcan Özeke, MD  
Diyarbakır Asker Hastanesi Kardiyoloji Kliniđi Diyarbakır, Turkey  
Mobile:+90 505 383 67 73 E-mail: ozcanozeke@gmail.com

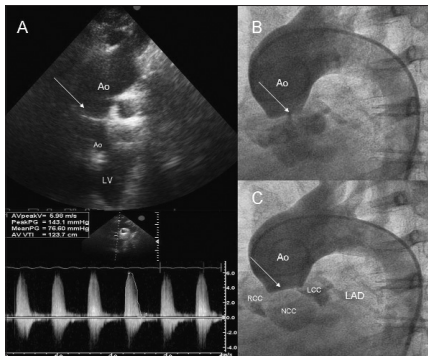


Figure 1. Transthoracic echocardiogram (A) and aortogram (B, C) showing a discrete fibrous membrane (arrows) above sinuses of Valsalva

Ao- aorta, LV- left ventricle, RCC- right coronary cusp, LCC- left coronary cusp, NCC- non-coronary cusp, LAD- left anterior descending artery

## A rare radiodiagnostic finding: totally and severely calcified aorta-the Porcelain aorta

### Nadir bir radyodiyagnostik bulgu: Bütünüyle ve ciddi şekilde kalsifiye aorta-Porselen aorta

An octogenarian male was referred to our department with effort angina refractory to optimal medical therapy. He had also relatively recurrent episodes of unstable angina pectoris. His physical examination was unremarkable. The electrocardiogram revealed non-specific ST segment and T wave changes. The chest X-ray showed a calcific ring at arcus aorta level. Then the patient was referred to catheterization laboratory for selective coronary angiography. During catheterization we realized that the entire aorta, from the iliac bifurcation to aortic cusps, had severe calcification resembling a porcelain tube (Fig.1, Video 1. See corresponding video/movie images at [www.anakarder.com](http://www.anakarder.com)). In addition, selective coronary angiography showed atherosclerotic stenotic segments of the major epicardial coronary arteries.

Atherosclerosis and calcification are related conditions. The more calcification, the more atherosclerosis and vice versa. Atherosclerotic plaques and areas of calcification of the aorta are relatively common in the elderly. However complete and severe calcification of the entire aorta is a rare condition. Actually, this is a clinically silent pathology. On the other hand during aortic valve replacement or coronary artery bypass surgery (CABG), rigidity of the aorta becomes a problem causing cerebral embolization and cerebrovascular accident. The operative management of a patient with porcelain aorta is often difficult and complex. Due to an unclampable aorta, aortic no-touch techniques, such as in situ arterial grafting without cardiopulmonary bypass (off-pump CABG), apicoaortic conduit, endoaortic balloon or Foley catheter occlusion, and aortic valve replacement under profound hypothermic circulatory arrest are different surgical options.

In conclusion, a surgeon who encounters a porcelain aorta at operation must quickly choose a safe and suitable operative method. So, a cardiologist might detect the calcification of the aorta and inform the surgeon about it before the operation.

Serkan Çay  
Department of Cardiology, Yüksek İhtisas Heart Education and  
Research Hospital, Ankara, Turkey

Address for Correspondence/Yazışma Adresi: Dr. Serkan Çay, Obası Sokak 11/6  
Hürriyet Apt. Cebeci 06480, Ankara, Turkey Phone: +90 312 319 65 68  
Mobile: +90 505 501 72 88 Fax: +90 312 287 23 90 E-mail: cayserkan@yahoo.com

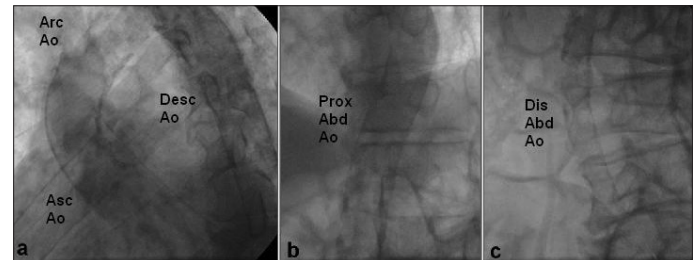


Figure 1. A. An instantaneous image from initial frames of cineangiography of the porcelain aorta

Asc Ao- ascending aorta, Arc Ao- arcus aorta, Desc Ao- descending aorta

B. An instantaneous image from middle frames of cineangiography of the porcelain aorta.

Prox Abd Ao- proximal abdominal aorta

C. An instantaneous image from last frames of cineangiography of the porcelain aorta

Dis Abd Ao- distal abdominal aorta