

Severe Diarrhea After Atrial Fibrillation Ablation and The Role of Vagal Plexus: A Case Series

INTRODUCTION

Percutaneous catheter ablation, a well-established intervention for treating atrial fibrillation (AF), carries the potential for gastrointestinal (GI) complications due to the proximity of the esophageal vagal plexus and the left atrium (LA). These complications typically manifest in the upper GI tract. However, lower GI tract involvement is markedly less prevalent, with only a few case reports in the literature. This case series presents the cases of 3 patients undergoing AF ablation and subsequently presented with severe diarrhea and an inability to reach the toilet due to increased intestinal motility, which began in the days following the procedures.

CASE REPORTS

Case 1

A 61-year-old female patient underwent catheter ablation for paroxysmal AF. The 4 pulmonary veins were successfully isolated by the cryoballoon technique (Figure 1). No additional treatment was performed at any other site within the LA. The patient was discharged from the hospital after a single night's observation.

One month later, during the follow-up visit, the patient reported persistent diarrhea and difficulty in reaching the toilet, which had started immediately following her discharge. The diarrhea was watery, odorless, and non-hemorrhagic. No preceding causes were identified, such as inflammatory bowel disease, food poisoning, or medication use. Laboratory investigations did not reveal any electrolyte disturbances. The immediate onset of symptoms following ablation prompted the consideration of a potential complication related to the procedure. Given the potential for esophageal vagal plexus stimulation during ablation, amitriptyline 25 mg as a single daily dose was initiated, given its robust anticholinergic effects. Following a 2-week interval, the patient's symptoms had resolved. The drug was continued for an additional 1 month, with the dose gradually tapered over time. At each clinic visit, the patient reported no further symptoms.

Case 2

A 65-year-old male patient with paroxysmal AF was admitted to the catheter laboratory. Using radiofrequency (RF) energy, all 4 pulmonary veins were successfully isolated from the antral region, and no other areas of the LA were treated (Figure 2A and B). The patient was discharged after an overnight follow-up.

On the third day following discharge, the patient complained of severe diarrhea. No electrolyte disturbance was identified in the laboratory findings. The patient was also initiated on a regimen of amitriptyline 25 mg as a single daily dose. Following a 10-day interval, the patient reported that their symptoms had resolved. As in Case 1, the drug was continued for a further month, with the dose gradually reduced over time. At each subsequent clinic visit, the patient reported no symptoms.

Case 3

A 62-year-old female patient with a prior history of cryoballoon-based AF ablation for paroxysmal AF was admitted to the catheter laboratory. During a routine

CASE REPORT

Uğur Nadir Karakulak 

Cem Çöteli 

Hikmet Yorgun 

Kudret Aytemir 

Department of Cardiology, Faculty of Medicine, Hacettepe University, Ankara, Türkiye

Corresponding author:

Uğur Nadir Karakulak
✉ ukarakulak@gmail.com

Cite this article as: Karakulak UN, Çöteli C, Yorgun H, Aytemir K. Severe diarrhea after atrial fibrillation ablation and the role of vagal plexus: A case series. *Anatol J Cardiol.* 2025;XX(X):1-4.



Copyright©Author(s) - Available online at anatoljcardiol.com.
Content of this journal is licensed under a Creative Commons Attribution-NonCommercial 4.0 International License.

DOI:10.14744/AnatolJCardiol.2025.4722

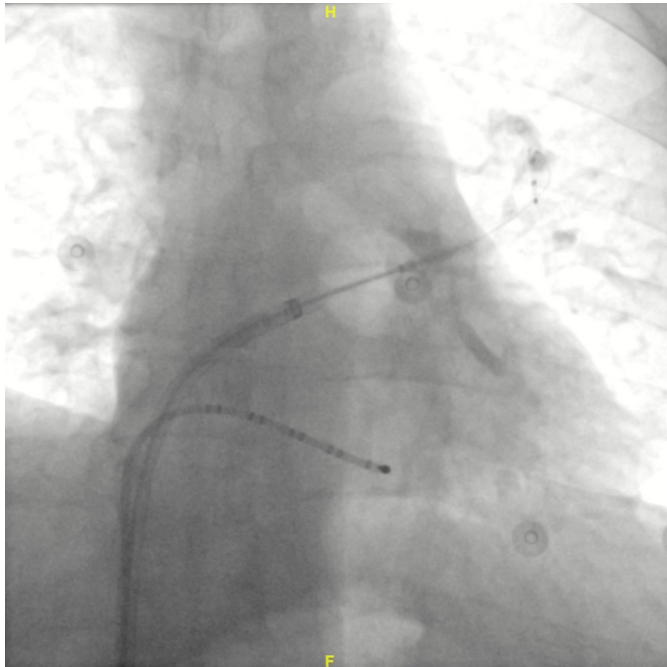


Figure 1. Fluoroscopic cryoballoon ablation image of Case 1.

evaluation of the LA substrate and identifying low-voltage areas before applying RF, a low-voltage area was identified on the roof of the LA. After pulmonary vein isolation, an iatrogenic corridor was created. Furthermore, an empirical roof line was established, and bidirectional block across the roof line was successfully confirmed (Figure 2C and D). The

patient was discharged following an overnight follow-up period.

On the second day following discharge, the patient presented with severe, watery, and odorless diarrhea. No electrolyte disturbance was identified in the laboratory tests. The patient was observed in the hospital for 2 days with intravenous hydration and was discharged with hyoscine butyl bromide 10 mg, a drug known for its strong anticholinergic effect. After a 1-week interval, the patient reported a resolution of their symptoms.

DISCUSSION

This case series presents 3 patients experiencing a highly unusual complication of AF ablation—severe diarrhea and an inability to reach the toilet due to increased intestinal motility. Patients were treated with 2 distinct anticholinergic agents, with the mechanism of action presumed to be cholinergic hyperactivation. This series is the first in the literature to observe symptoms at an early stage following ablation with both cryoballoon and RF, and a complete response was achieved with different agents, amitriptyline and hyoscine butylbromide, targeting the potential mechanism.

The proximity of the esophagus to the LA posterior wall makes it a potential site of injury during catheter ablation of AF, leading to various GI complications.¹ However, there is a paucity of data regarding the prevalence and diagnostic approach to vagal nerve injury following ablation therapy for AF. In a large registry, the overall incidence of GI complications following AF ablation was extremely low (0.74% of the patient cohort) in a single center.² Furthermore,

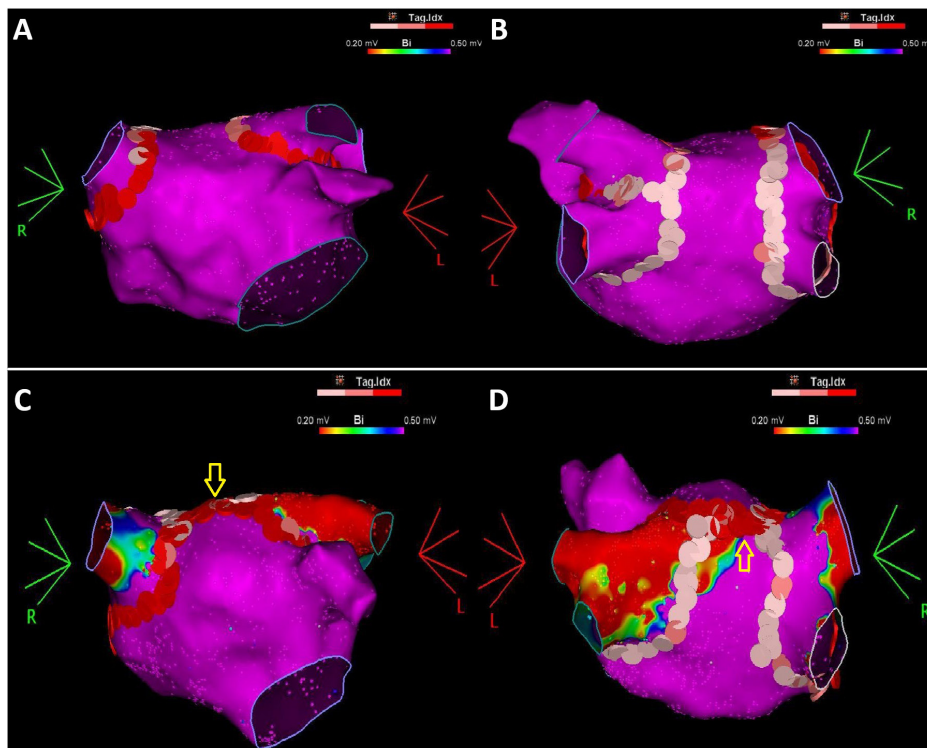


Figure 2. Three-dimensional electroanatomic mapping and RF tags images of Case 2 (A, from anterior and B, from posterior perspectives) and Case 3 (C, from anterior and D, from posterior perspectives). Yellow arrows show the roof line ablation.

these structural and anatomical complications are confined almost entirely to the upper GI tract, including atrio-esophageal fistula, gastroparesis, esophageal thermal lesions, and esophageal ulcers.³

The functional complications probably result from the effects of RF energy delivered to the LA on the periesophageal vagal plexus. This plexus provides autonomic innervation to the mid and lower esophagus and transmits parasympathetic fibers to the abdomen (Figure 3). The parasympathetic efferents originating from the vagal plexus are associated with the contraction of enteric smooth muscle, the inhibition of the sphincters, and the increased secretion of lubricating mucus by submucosal glands.⁴ In the present case series, the complaints related to increased GI motility that began shortly after ablation may be attributable to hyperactivation of the vagal plexus by both cryo and RF energy. The complete clinical responses to anticholinergic drugs provide evidence of this mechanism. Another perspective to vagal activation due to ablation may be its modulatory effects on the sympathetic/parasympathetic balance through the left atrial ganglionated plexus. Autonomic nervous system modification can be achieved through cryoablation, and vagal reactions during AF ablation are associated with reduced recurrence of atrial tachyarrhythmias. From this perspective, AF ablation-induced autonomic nervous system modulation and the resulting shift in the balance between the sympathetic and parasympathetic systems could potentially explain the occurrence of GI symptoms.⁵

Yamane et al⁶ reported 3 cases of persistent diarrhea following ablation. In contrast to our cases, the patients in this series

manifested relatively late (after 2 to 3 weeks). Additionally, they had hypokalemia, which was treated with electrolyte replacement, serotonin receptor antagonists, and various extract granules. In our cases, the onset of diarrhea was on the second or third day following the procedure. Only Case 1 presented with diarrhea and more predominantly inability to reach the toilet in the first month. Accordingly, neither weight loss nor electrolyte imbalance was seen in our patients. A further case report documented a patient with esophageal hypercontractility following RF ablation.⁷ The case, successfully treated with a calcium channel blocker, is similar to our case regarding the mechanism of "vagal nerve stimulation." However, there was no evidence of "lower" GI tract hyperactivation.

The factors associated with the AF ablation procedure should be taken into account to ascertain the causal relationship between AF ablation and vagal response. In our center, cryoenergy was applied for 240 seconds to the left superior and inferior pulmonary veins and for 180 seconds to the right superior and inferior pulmonary veins in patients undergoing cryoablation. Additionally, the phrenic capture test was routinely performed when isolating the right pulmonary veins with cryoablation as a safety precaution, but evidence of damage that would require stopping the ablation suddenly during the procedure was not observed in Case 1. In patients undergoing AF ablation with RF energy, the power was set to 40 watts, with a target contact force of 10-15 grams. Radiofrequency energy was applied for 20-25 seconds to the roof. Lesion quality was monitored using the CLOSE protocol and Ablation Index (Cases 2 and 3). Although the procedure was performed in accordance with valid and safe standard protocols, the observation of such an adverse effect indicates that it may be more frequent than previously assumed and that patients should be queried about this adverse effect during follow-up.

CONCLUSION

The proximity of the LA and pulmonary veins to the posteriorly localized esophageal vagal plexus can lead to distinct functional GI tract symptoms in patients. Damage to the vagal nerve can result in both hypo- and hyperactivation. It is crucial to be vigilant in monitoring patients following ablation procedures, as complications such as severe diarrhea have the potential to significantly impair quality of life and even pose a life-threatening risk.

Informed Consent: Detailed information was given to the patients regarding the possible contribution of the case report to the literature. The patients gave written and verbal consent for the publication of the case report.

Declaration of Interests: The authors have no conflicts of interest to declare.

Funding: The authors declare that this study received no financial support.

Use of AI for Writing Assistance: Artificial intelligence was not used in this study.

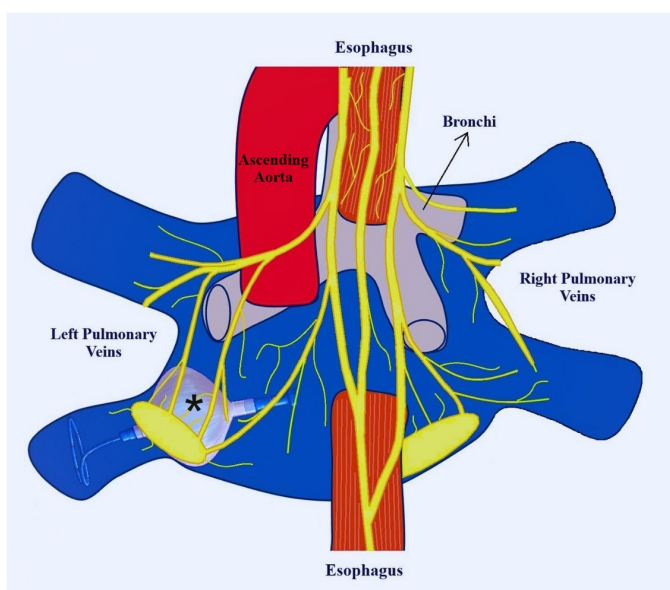


Figure 3. The posterior aspects of the LA shows the proximity of the esophagus, vagal plexus, and the LA. This anatomical proximity makes the vagal plexus a target for the energy delivered during AF ablation. A balloon positioned to deliver cryoenergy at the ostium of the left inferior pulmonary vein is shown as an asterisk.

REFERENCES

1. Sánchez-Quintana D, Cabrera JA, Climent V, Farré J, Mendonça MC, Ho SY. Anatomic relations between the esophagus and left atrium and relevance for ablation of atrial fibrillation. *Circulation*. 2005;112(10):1400-1405. [\[CrossRef\]](#)
2. Park SY, Camilleri M, Packer D, Monahan K. Upper gastrointestinal complications following ablation therapy for atrial fibrillation. *Neurogastroenterol Motil*. 2017;29(11). [\[CrossRef\]](#)
3. Garg L, Garg J, Gupta N, et al. Gastrointestinal complications associated with catheter ablation for atrial fibrillation. *Int J Cardiol*. 2016;224:424-430. [\[CrossRef\]](#)
4. Lakkireddy D, Reddy YM, Atkins D, et al. Effect of atrial fibrillation ablation on gastric motility: the atrial fibrillation gut study. *Circ Arrhythm Electrophysiol*. 2015;8(3):531-536. [\[CrossRef\]](#)
5. Yorgun H, Aytemir K, Canpolat U, Şahiner L, Kaya EB, Oto A. Additional benefit of cryoballoon-based atrial fibrillation ablation beyond pulmonary vein isolation: modification of ganglionated plexi. *Europace*. 2014;16(5):645-651. [\[CrossRef\]](#)
6. Yamane T, Inaba O, Hachisuka E, Yamashita S, Yoshimura M, Nitta JI. Persistent diarrhea following catheter ablation for atrial fibrillation: a lesser-known complication of left atrial ablation procedures. *HeartRhythm Case Rep*. 2021;7(9):633-636. [\[CrossRef\]](#)
7. Tolone S, Savarino E, Docimo L. Radiofrequency catheter ablation for atrial fibrillation elicited "jackhammer esophagus": a new complication due to vagal nerve stimulation? *J Neurogastroenterol Motil*. 2015;21(4):612-615. [\[CrossRef\]](#)