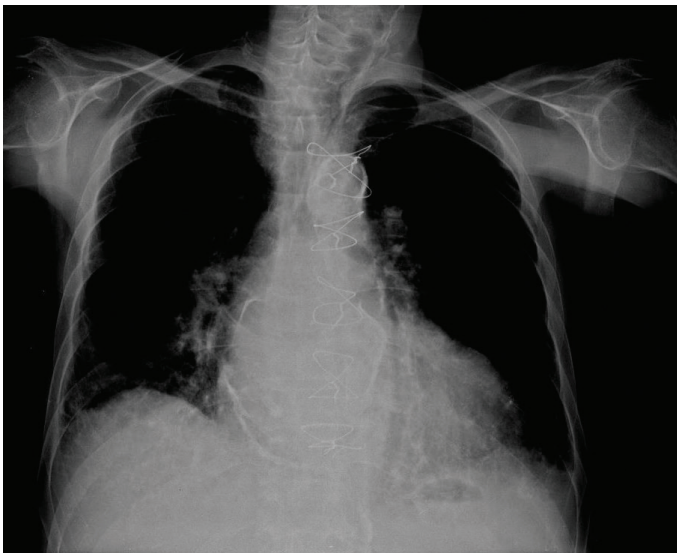


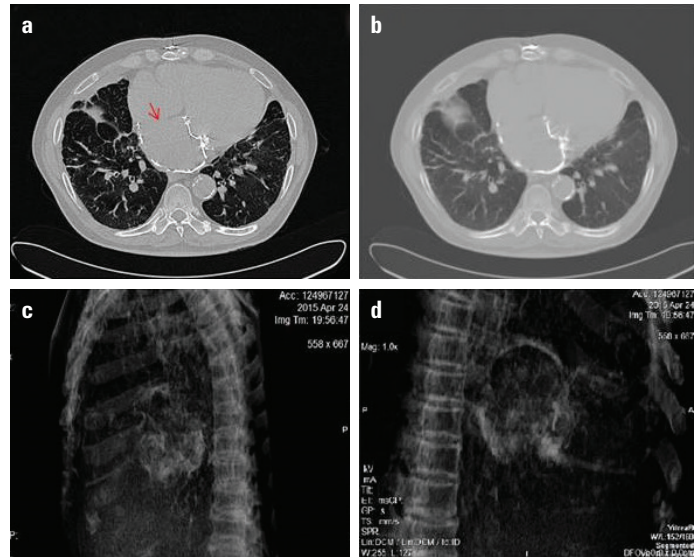
## A rare radiodiagnostic finding: Porcelain atrium

A 76-year-old male patient was admitted to our hospital for further cardiac evaluation for shortness of breath. His history revealed a mitral valve replacement via a left atrial (LA) approach 25 years ago for severe rheumatic mitral stenosis, diabetes mellitus, and persistent atrial fibrillation. There was no evidence of LA calcification at that time. Physical examination revealed crackles in both lung bases. Electrocardiography revealed atrial fibrillation rhythm with a ventricular rate of 78 beats/min. Chest radiography showed diffuse calcified outline of the LA wall (Fig. 1). Transthoracic echocardiography revealed a normally functioning prosthetic mitral valve and LA and left ventricular enlargement. Ejection fraction was 30%, subsequently, computed tomography (CT) of the thorax to delimit this finding was obtained, which confirmed calcification outlining the LA free wall. CT revealed extensive and diffuse calcification of the LA free wall, except in the interatrial septum, which has been described as a “porcelain atrium” (Fig. 2). Under conservative management including medications with diuretics and vasodilators, his symptoms improved.

Massive calcification of the LA wall, also known as “porcelain atrium” or “mold-like calcification,” is a rare condition commonly associated with long-standing rheumatic valve disease or extensive rheumatic pancarditis. The interatrial septum is often spared. Complete calcification of the LA wall including the interatrial septum is termed as “coconut atrium.” Although without immediate consequences, it predisposes to atrial fibrillation, embolization, and pulmonary congestion due to noncompliance of the LA. Familiarity with radiographic features of this unique



**Figure 1.** Chest radiography showing diffuse calcified outline of the left atrial wall



**Figure 2.** Multislice contrast-enhanced computed tomography (CT) of the thorax. Axial (a and b) and sagittal (c and d) images showing extensive and diffuse calcification outlining the LA free wall, except in the interatrial septum (red arrow)

distribution of calcium in the correct clinical setting will allow prompt recognition when interpreting chest X-rays and CT images. Present findings suggest that a long-standing rheumatic inflammation resulted in LA calcification after mitral valve replacement.

**Yalçın Velibey, Sinan Şahin\*, Tolga Sinan Güvenç, Özlem Yıldırım Türk**

**Departments of Cardiology and \*Radiology, Siyami Ersek Thoracic and Cardiovascular Surgery Center, Training and Research Hospital, İstanbul-Turkey**

**Address for Correspondence:** Dr. Yalçın Velibey

Dr. Siyami Ersek Hastanesi, Tıbbiye Cad. No:25

Üsküdar / İstanbul-Türkiye

Phone: +90 216 444 52 57

Fax: +90 216 337 97 19

E-mail: dr\_yalchin\_dr@yahoo.com.tr

©Copyright 2017 by Turkish Society of Cardiology - Available online at [www.anatoljcardiol.com](http://www.anatoljcardiol.com)

DOI:10.14744/AnatolJCardiol.2017.8115

## A rare cause of pericardial tamponade: Chylopericardium 🎥

A 56-year-old woman presented at our emergency clinic with dyspnea. She had a history of lung carcinoma, which was diagnosed 2 weeks ago. She was advised chemotherapy, but she did not start the treatment. Her blood pressure, heart rate, respiration rate, and oxygen saturation were 95/55 mm Hg, 103 beats/min, 18 breaths/min, and 92%, respectively. Her physical examination