

returned after 1 year. Re-catheterization again showed high PVRI and she had developed right-to-left shunting. Medical follow-up was continued and the probable need for heart-lung transplantation in the future was discussed.

Discussion

In this study, the APW patient had survived until the fourth decade of life. The literature suggests that APW is associated with a high mortality rate and the median survival of uncorrected APW is 33 years (2). Furthermore, APW patients usually become symptomatic, develop Eisenmenger syndrome, and show signs of progressive pulmonary arterial hypertension in the first month of life (2, 3). Conversely, our patient remained asymptomatic until 31 years of age and presented as non-Eisenmenger. To our knowledge, very few "asymptomatic" adult cases have been reported in the literature (2-5). APW patients usually have associated cardiac disorders, such as an atrial septal defect, patent ductus arteriosus, ventricular septal defect, coronary artery anomaly, or tetralogy of Fallot (1). However, our patient had an isolated APW. The present case is also very unique as it describes the role of 3D printing technology in the decision-making for the management of the APW. 3D printing technology has opened up new opportunities in cardiology and cardiac surgery (6-9). Conventionally, APW is diagnosed with echocardiography, cardiac CT, CMRI, and a catheterization study (2, 3). However, a 3D anatomical model of the patient's heart provided invaluable information compared to the conventional modalities used in our case. We strongly believe that 3D printing technology will play a significant role in the imaging, planning, and performance of cardiovascular interventions.

Conclusion

We report an unusual case of a 32-year-old female with a large, unrepaired APW causing severe pulmonary hypertension. The case is unique in terms of the asymptomatic period until the fourth decade of life, the long survival with an unrepaired APW, presentation as non-Eisenmenger, and an APW as an isolated congenital defect. Furthermore, to the best of our knowledge, this is the first case in literature to have utilized 3D printing technology to assess the fine details of the defect and to aid in the management of a patient with an APW.

References

- Chellappan S, Katewa A, Sathe YC. Transesophageal Echocardiography in a Distal Aortopulmonary Window. *J Cardiovasc Echogr* 2016; 26: 131-4.
- Kose M, Ucar S, Emet S, Akpınar TS, Yalin K. A Case of Aortopulmonary Window: Asymptomatic until the First Pregnancy. *Case Rep Cardiol* 2015; 2015: 935253.
- Aggarwal SK, Mishra J, Sai V, Iyer VR, Panicker BK. Aortopulmonary window in adults: diagnosis and treatment of late-presenting patients. *Congenit Heart Dis* 2008; 3: 341-6.
- Gowda D, Gajjar T, Rao JN, Chavali P, Sirohi A, Pandarinathan N, et al. Surgical management of aortopulmonary window: 24 years of experience and lessons learned. *Interact Cardiovasc Thorac Surg* 2017; 25: 302-9.
- Myers PO, Lador F, Hachulla AL, Bouchardy J, Noble S, Licker M, et al. Unrestrictive Aortopulmonary Window: Extreme Presentation as Non-Eisenmenger in a 30-Year-Old Patient. *Circulation* 2016; 133: 1907-10.
- Bartel T, Rivard A, Jimenez A, Mestres CA, Müller S. Medical three-dimensional printing opens up new opportunities in cardiology and cardiac surgery. *Eur Heart J* 2017 Feb 16; doi: 10.1093/eurheartj/ehx016.
- Bramlet M, Olivieri L, Farooqi K, Ripley B, Coakley M. Impact of Three-Dimensional Printing on the Study and Treatment of Congenital Heart Disease. *Circ Res* 2017; 120: 904-7.
- Olejnik P, Nosal M, Havran T, Furdova A, Cizmar M, Slabej M, et al. Utilisation of three-dimensional printed heart models for operative planning of complex congenital heart defects. *Kardiol Pol* 2017; 75: 495-501.
- Vukicevic M, Mosadegh B, Min JK, Little SH. Cardiac 3D Printing and its Future Directions. *JACC Cardiovasc Imaging* 2017; 10: 171-84.

Address for Correspondence: Dr. Aniketh Vijay Balegadde

Department of Cardiology, Amrita Institute of Medical Sciences,

Amrita Vishwa Vidyapeetam University,

682041 Kochi; Kerala-India

Phone: +91-8762577777

E-mail: aniketh.vijay7@gmail.com

©Copyright 2018 by Turkish Society of Cardiology - Available online

at www.anatoljcardiol.com

DOI:10.14744/AnatolJCardiol.2017.7948



Valve-sparing aortic root replacement in Loeys-Dietz syndrome and a novel mutation in TGFBR2

Taner Kasar, Alper Gezdirici¹, Pelin Ayyıldız, Sertaç Haydin*, Alper Güzeltaş

Department of Pediatric Cardiology, *Cardiovascular Surgery, İstanbul Mehmet Akif Ersoy Thoracic and Cardiovascular Surgery Training and Research Hospital; İstanbul-Turkey

¹Department of Medical Genetics, Kanuni Sultan Süleyman Training and Research Hospital; İstanbul-Turkey

Introduction

Loeys-Dietz syndrome (LDS) is a rare, multisystemic, autosomal dominant connective tissue disease coursing with a progressive aortic root aneurysm. Despite the lack of definitive criteria, LDS is characterized by the triad of arterial tortuosity/aneurysm, hyper-telorism, and bifid uvula or cleft palate, and shows genetic heterogeneity. In previous studies, mutations of the *TGFBR1*, *TGFBR2*, *SMAD3*, and *TGFBR2* genes have been reported in LDS. Mutations in these genes cause dysregulation of the TGFβ pathway (1, 2).

Presently described is a novel *TGFBR2* gene mutation that was detected in a child with a giant aortic aneurysm, which was treated with valve-sparing aortic root replacement.

Case Report

A 12-year-old male patient with a murmur and pectus carinatum was referred to the hospital. There was no consanguinity and the family history was negative. He had dysmorphic features of dolichocephaly, down-slanting palpebral fissures, micrognathia, thick and bifid uvula, significant pectus carinatum, arachnodactyly, and scoliosis.

Despite normal tricuspid morphology, there was severe regurgitation of the aortic valve due to dilatation and a lack of coaptation observed in the echocardiographic evaluation. Mitral valve prolapse and mild mitral regurgitation were demonstrated. Fusiform dilatation of the aortic root and the ascending aorta was detected. The annulus was measured at 32 mm (Z-score: +10.5), sinus of Valsalva at 90 mm (Z-score: +12.6), and the ascending aorta at 51 mm (Z-score: +8.3) (Fig. 1a). The left ventricle end-diastolic and end-systolic diameter was 68 mm (Z-score: +4.77) and 49 mm (Z-score: +5), respectively.

A computed tomography (CT) evaluation revealed aneurysmatic dilatation from the aortic root to the right truncal brachiocephalic branch, 90 mm from the level of the sinus of Valsalva (Fig. 1b, 1c). *TGFBR2* gene analysis was planned with the suspicion of LDS.

A heterozygous missense p.Leu305Phe (c.913C>T) mutation was detected in the *TGFBR2* gene. The parents were found to be wild type (Fig. 2).

The patient was operated on with 34°C hypothermia. Valve-sparing aortic root replacement (reimplantation technique with 28-mm Valsalva graft-David operation) and ascending aorta graft replacement were performed (Fig. 3a, 3b). Cardiopulmonary bypass time was 130 minutes, and the mean aortic cross-clamp time was 110 minutes. The patient was discharged at the end of the first postoperative week without any complication. There

were no significant symptoms during 6 months of follow-up in which echocardiographic findings revealed only mild to moderate aortic insufficiency with an ejection fraction of 56% and a shortening fraction of 30%.

Discussion

The new mutation missense p.Leu305Phe (c.913C>T) mutation in the *TGFBR2* gene detected in our patient, to the best of our knowledge, has not been reported before. The in silico prediction tools (Alamut, MutationTaster, PolyPhen-2, and SIFT) classify this mutation as a highly probable pathogenic mutation, as it is located within a highly conserved region.

LDS is characterized by cardiovascular, skeletal, and ocular system abnormalities, and diagnosis should be confirmed with molecular tests, as there are no specific clinical criteria for diagnosis. While some of the known mutations are aggressive, others usually have a mild course. In previous reports, authors have emphasized that a 4-cm intervention was appropriate in LDS patients with more lethal mutations, but they also highlighted that even among these patients who have a more aggressive phenotype and particularly bad acting mutations, it would be beneficial to proceed with a root replacement at diameters of around 2 cm (3). In another report, it was suggested that at centers with experienced staff and the ability to perform a valve-sparing procedure, surgery should be considered for young children, especially in cases of aggressive phenotypes, once the maximal dimension of the ascending aorta exceeds the 99th percentile and the diameter of the aortic annulus exceeds 1.8 cm (1). The progressive increase in aortic root Z-scores of our patient up to +10 might be an indicator of the aggressive nature of the recently diagnosed mutation.

Overall, aggressive connective tissue disorders such as LDS require earlier than usual surgical intervention in the cardiovascular system. Reports suggest a comprehensive, multidisciplinary, aggressive approach to the surgical treatment of aortic disease in patients with LDS. During follow-up,

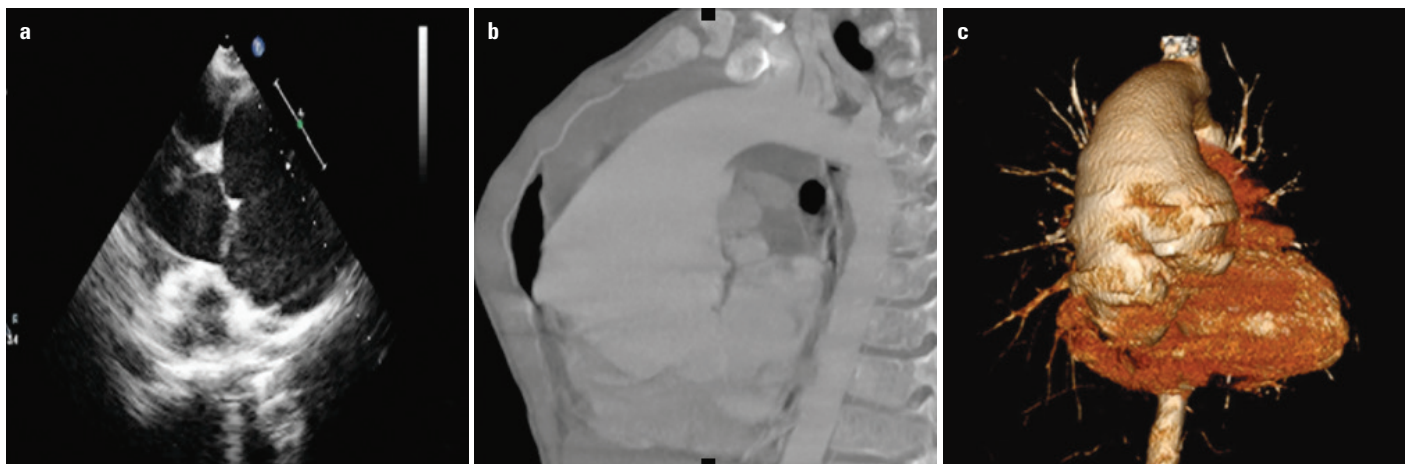


Figure 1. (a) The fusiform dilatation of the sinus of Valsalva in echocardiographic evaluation. (b, c) The aneurysmatic dilatation of the aortic root and arcus aorta on computed tomography angiographic images

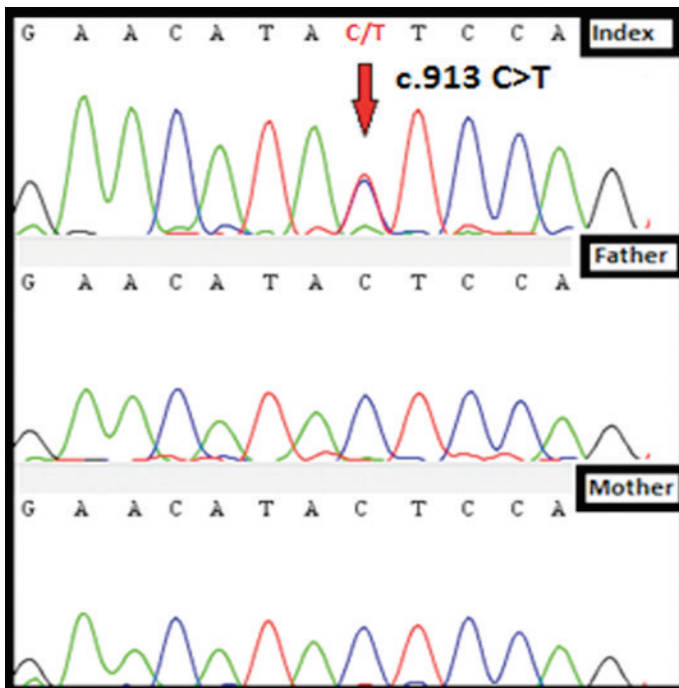


Figure 2. Sequence images of exon 4 in the *TGFBR2* gene

one-quarter of the patients are expected to require surgical reintervention due to the nature of this inherent disorder (3, 4).

Valve-sparing root replacement has become a safe and reliable option for LDS patients with a low risk of mortality and need for reoperation of the aortic root (3, 4). Valve-sparing root replacement can be performed in all but patients with acute dissection and unstable hemodynamics, bicuspid aortic valves with extensive calcification, severe leaflet fenestration, or leaflet asymmetry (3). Unlike the increased risk of aortic dissection at or above the 5.0 cm aortic root dimension in Marfan syndrome, dissections have occurred in individuals with LDS type I, II, or III at aortic dimensions of 3.9 cm to 4.0 cm, and have been reported in LDS type IV at a dimension <5.0 cm (1, 5, 6). The dimensions of the aortic root of our patient were already greater than the specified indications for surgery. As our patient was very young, to prevent complications of the prosthetic valve and coumadinization, valve-sparing surgery was preferred.

Conclusion

The novel p.Leu305Phe (c.913C>T) mutation in the *TGFBR2* gene determined in the present case, which exhibited a malignant course, contributes additional data to the unknown spectrum of mutations in LDS. We believe that much earlier aggressive treatment is needed in selected patients with aggressive mutations.

References

1. Loeys BL, Schwarze U, Holm T, Callewaert BL, Thomas GH, Pannu H, et al. Aneurysm syndromes caused by mutations in the TGF-beta

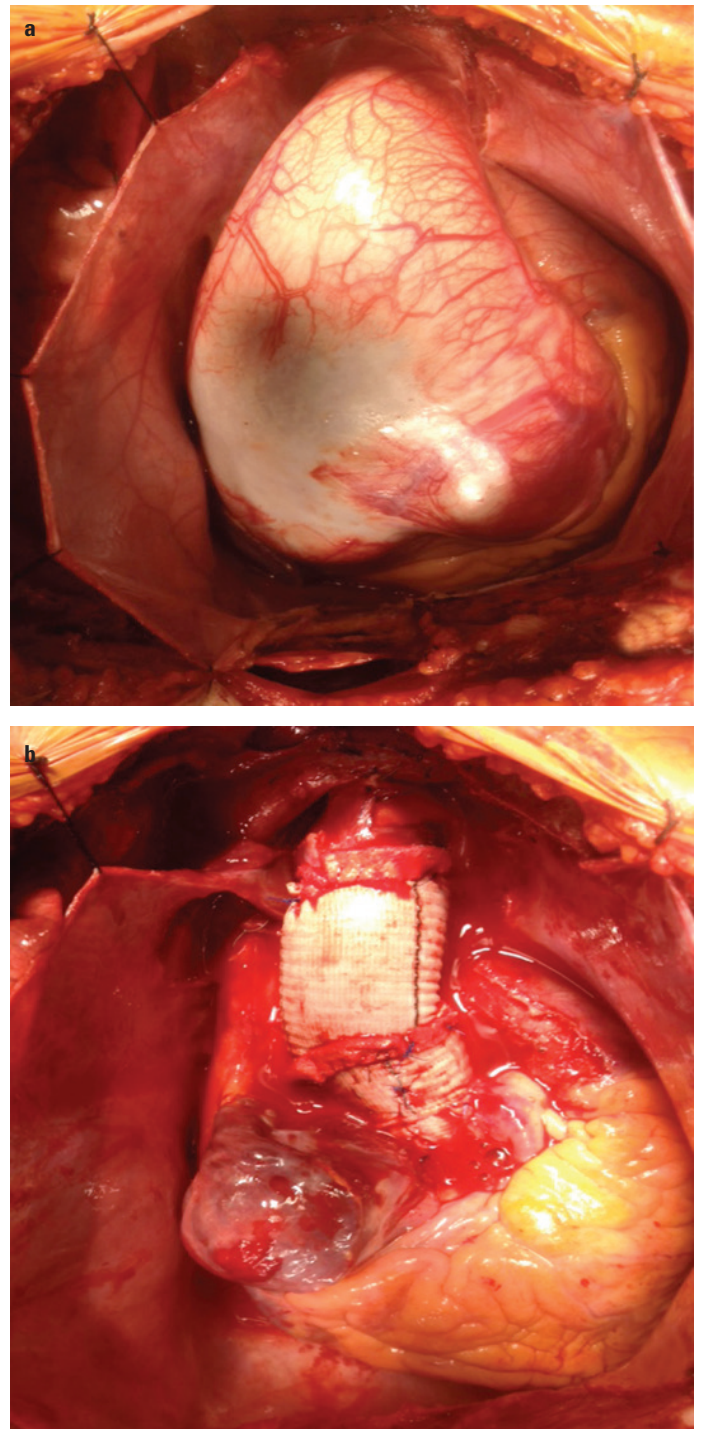


Figure 3. (a) Preoperative and (b) postoperative view of the aortic root

- receptor. *N Engl J Med* 2006; 355: 788-98. [CrossRef]
2. MacCarrick G, Black JH 3rd, Bowdin S, El-Hamamsy I, Frischmeyer-Guerrero PA, Guerrero AL, et al. Loeys-Dietz syndrome: a primer for diagnosis and management. *Genet Med* 2014; 16: 576-87. [CrossRef]
3. Patel ND, Alejo D, Crawford T, Hibino N, Dietz HC, Cameron DE, et al. Aortic Root Replacement for Children With Loeys-Dietz Syndrome. *Ann Thorac Surg* 2017; 103: 1513-8. [CrossRef]
4. Patel ND, Crawford T, Magruder JT, Alejo DE, Hibino N, Black J, et al. Cardiovascular operations for Loeys-Dietz syndrome: Intermediate-

- term results. J Thorac Cardiovasc Surg 2017; 153: 406-12. [CrossRef]
5. van de Laar IM, Oldenburg RA, Pals G, Roos-Hesselink JW, de Graaf BM, Verhagen JM, et al. Mutations in SMAD3 cause a syndromic form of aortic aneurysms and dissections with early-onset osteoarthritis. Nat Genet 2011; 43: 121-6. [CrossRef]
 6. Renard M, Callewaert B, Malfait F, Campens L, Sharif S, del Campo M, et al. Thoracic aortic-aneurysm and dissection in association with significant mitral valve disease caused by mutations in TGFB2. Int J Cardiol 2013; 165: 584-7. [CrossRef]

Address for Correspondence: Dr. Taner Kasar
İstanbul Mehmet Akif Ersoy, Göğüs Kalp ve Damar Cerrahisi
Araştırma ve Eğitim Hastanesi, Pediatrik Kardiyoloji Anabilim Dalı,
İstasyon Mah. Turgut Özal Bulvarı No:11 Halkalı,
İstanbul- Türkiye

Phone: +90 212 692 20 00-4061

E-mail: taner.kasar@hotmail.com

©Copyright 2018 by Turkish Society of Cardiology - Available online
at www.anatoljcardiol.com

DOI:10.14744/AnatolJCardiol.2017.7911

