

Cor calcium: heart trapped in a pericardial cage

A 47-year-old female patient was admitted to our hospital for the evaluation of shortness of breath. Her previous medical record was unremarkable. ECG revealed negative T waves in the inferior and precordial derivations (Fig. 1). Chest X-ray showed dense calcification around the heart, compatible with a calcified pericardium (Fig. 2a, b). Two-dimensional transthoracic echocardiogram revealed severe thickening and calcification of

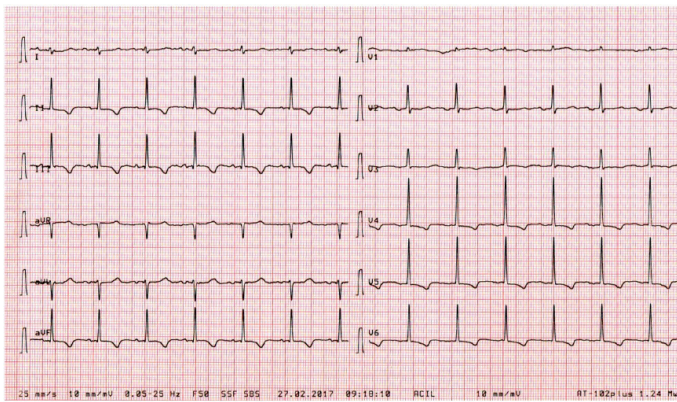


Figure 1. Electrocardiography showing negative T waves in the inferior and precordial derivations

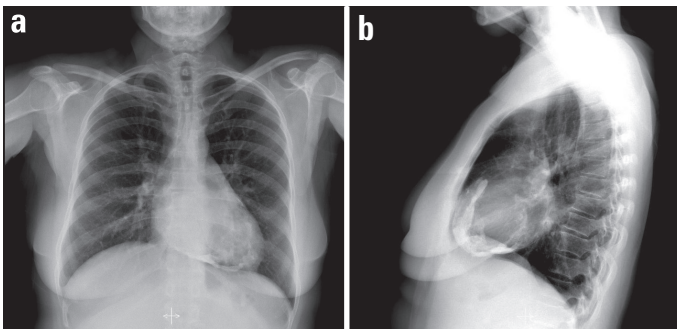


Figure 2. Chest X-ray (posteroanterior and lateral views) showing dense pericardial calcification

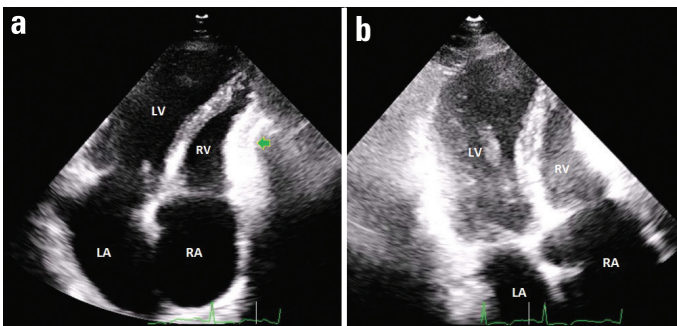


Figure 3. Two-dimensional transthoracic echocardiography showing severe thickening and calcification of the pericardium, leading to the strangulation of the heart. The calcification of the pericardium next to the basal and mid sections of the left ventricular free wall (a) and that next to the right ventricular free wall (b) are shown. Note that both the visceral and parietal pericardium are calcified

the pericardium, leading to the strangulation of the heart, but the extent of pericardial calcifications could not be estimated (Fig. 3a, b; Video 1). Constrictive physiology was also noted. In contrast, live/real-time three-dimensional transthoracic echocardiography (3-D-TTE) enabled the visualization of massive pericardial calcifications around both the ventricles and right atrium (Fig. 4a, b; Video 2), thus establishing a diagnosis of pericarditis constrictiva calcarea. A relative sparing of the anterior and apical aspects of both ventricles was noted. Routine laboratory test results revealed normal electrolyte levels and normal renal, liver, parathyroid, and thyroid functions. The levels of myocardial injury biomarkers and inflammatory and rheumatic disease markers were also normal. Tuberculosis was excluded based on negative results of the PPD test. Cardiac multidetector computed tomography confirmed the 3-D-TTE findings, with volume-rendered images showing severe pericardial calcification surrounding nearly both the ventricles and atria (Fig. 5). Coronary angiography revealed normal left and right coronary arter-

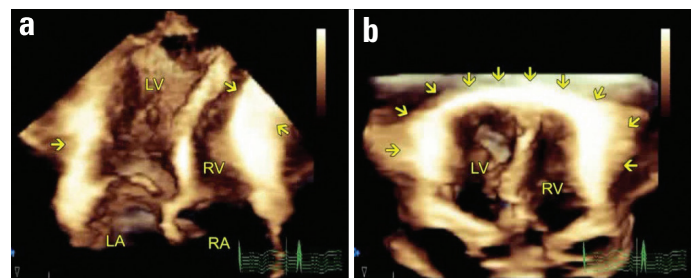


Figure 4. Three-dimensional (3-D) transthoracic imaging. The extent of pericardial calcification was better observed on three-dimensional echocardiograms. (a) The 3-D dataset was cropped to show the calcified pericardium next to the right ventricular (RV) free wall, causing a mild narrowing of the RV inflow; (b) the calcified pericardium surrounding both the ventricles were shown after cropping the 3-D dataset. Note the relative sparing of the anterior wall on the 3-D image

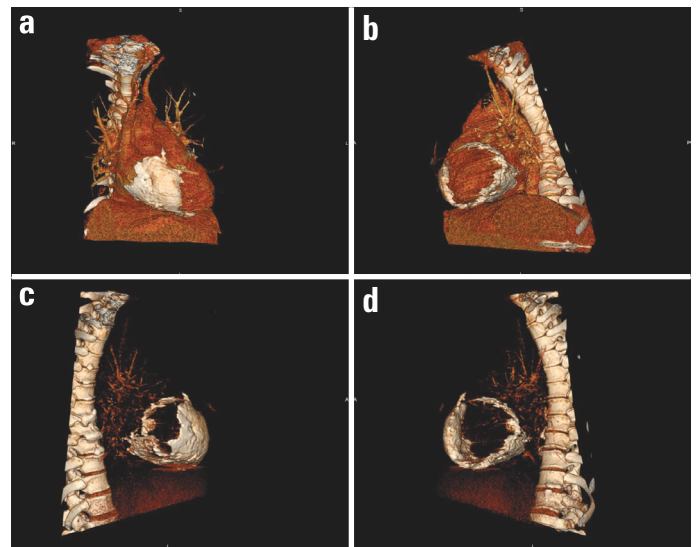


Figure 5. Cardiac multidetector computed tomography (a-d). Volume rendering reconstruction of cardiac structures showing severe pericardial calcification surrounding nearly both the ventricles and atria, resembling a trapped heart

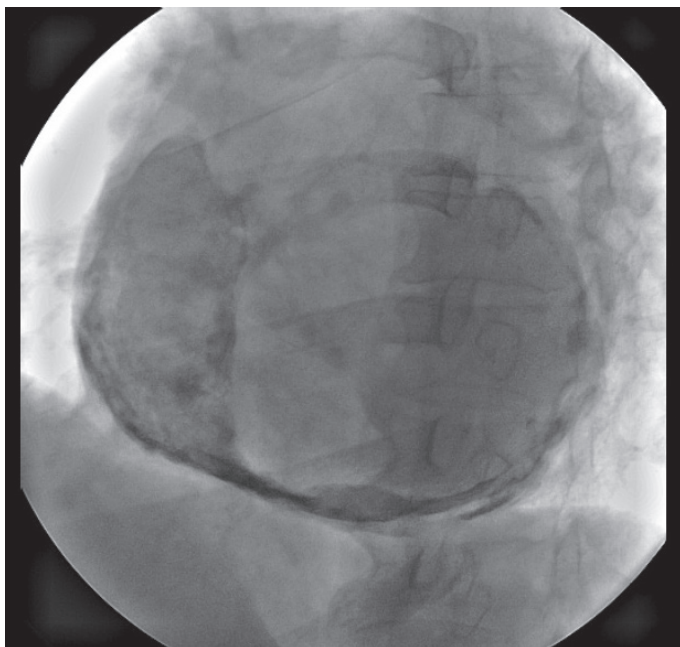


Figure 6. Fluoroscopic imaging showing severe calcification of the pericardium

ies, whereas fluoroscopic images revealed severe pericardial calcifications (Fig. 6a–d; Video 3). As a definitive treatment, we recommended pericardiectomy to the patient, but the patient refused operation.

This case illustrates a heavily calcified pericardium that surrounds both the ventricles and atria, resembling a trapped heart in a pericardial cage, and the use of a multimodality approach for the diagnosis and evaluation of the patient.

Video 1. Two-dimensional transthoracic echocardiography movie clips showing dense calcifications of the pericardium. The first movie clip shows calcification of the pericardium next to the basal and mid sections of the left ventricular (LV) free wall. In the second movie clip, calcification of the pericardium next to the right ventricular (RV) free wall is shown. Note that both

visceral and parietal pericardium are calcified. In the final clip, a dilated inferior vena cava (IVC) that did not collapse with inspiration is shown. Arrows show pericardial calcifications. Bouncing of the interventricular septum during early diastole is observed in the first two clips. LA, left atrium; RA, right atrium.

Video 2. Three-dimensional (3-D) transthoracic images showing pericardial calcification surrounding both the ventricles. In the first image clip, the 3-D dataset was cropped to show calcified pericardium next to the right ventricular (RV) free wall, causing a mild narrowing of the RV inflow. The second image clip is a modification of the first image, with different gain and image settings to attenuate myocardial echogenicity to emphasize on the calcified pericardium next to the left ventricular (LV) posterior wall. In the third and fourth image clips, calcified pericardium surrounding both ventricles is shown after cropping the 3-D dataset. The fifth image clip is similar to the fourth image clip, except that the gain and image settings are adjusted to attenuate myocardial echogenicity to demonstrate calcified pericardium next to the LV posterior wall. Note that a septal bounce is evident in all movie clips, thus suggesting the presence of a constrictive physiology. The pericardium next to the anterior surface of the heart is spared. Arrows show pericardial calcifications. LA - left atrium; RA - right atrium.

Video 3. Fluoroscopy showing severe calcification of the pericardium.

Yalçın Velibey, Sinan Şahin*, Tolga Sinan Güvenç, Tolga Onuk
Departments of Cardiology and *Radiology, Siyami Ersek
Thoracic and Cardiovascular Surgery Center, Training and
Research Hospital; İstanbul-Turkey

Address for Correspondence: Dr. Yalçın Velibey
Dr. Siyami Ersek Göğüs ve Kalp Damar Cerrahisi Hastanesi
Kardiyoloji Bölümü, Tıbbiye Cad. No:25
Üsküdar, İstanbul-Türkiye
Phone: +90 216 444 52 57 Fax: +90 216 337 97 19
E-mail: dr_yalchin_dr@yahoo.com.tr
©Copyright 2017 by Turkish Society of Cardiology - Available online
at www.anatoljcardiol.com
DOI:10.14744/AnatolJCardiol.2017.7979