

Video 5. 3D-Transesophageal echocardiography in midesophageal long-axis view showed the left atrial mass (arrow)

Ahmet Karaduman*, **Ismail Balaban***, **Berhan Keskin***,
Çetin Geçmen*, **Mehmet Erdem Tokar****

Departments of *Cardiology, and **Cardiovascular Surgery, Kartal Koşuyolu Training and Research Hospital; İstanbul-Turkey

Address for Correspondence: Dr. Ahmet Karaduman,
Kartal Koşuyolu Yüksek İhtisas Eğitim ve Araştırma Hastanesi,
Kardiyoloji Kliniği, Denizer Caddesi,
Cevizli Kavşağı No: 2,
Kartal, İstanbul-Türkiye
E-mail: ahmetkaraduman91@gmail.com
©Copyright 2019 by Turkish Society of Cardiology - Available online
at www.anatoljcardiol.com
DOI:10.14744/AnatolJCardiol.2019.80195

A suspicious left atrial mass in a patient with stroke: Hiatal hernia 🎬

A 74-year-old woman was admitted to the neurology department with a history of syncope. Her medical history included diabetes mellitus and hypertension. Electrocardiography showed normal sinus rhythm. Cranial magnetic resonance imaging revealed acute corpus callosum infarction. To identify the potential cardioembolic source, we performed transthoracic echocardiography (TTE), which revealed a large, well-circumscribed, heterogeneous, echodense mass (4.1 cm×3.5 cm) thought to be within the left atrium (LA) (Fig. 1, Video 1). In order to visualize the structure better, we performed transesophageal echocardiography, but no mass was detected in LA (Video 2). Chest computed tomography (CT) revealed an extrinsic, inhomogeneous, large structure located posteriorly to the LA, consistent with a hiatal hernia (HH) (without an intracardiac mass) (Fig. 2). A 24-hour rhythm holter revealed paroxysmal atrial fibrillation. Therefore, anticoagulation was initiated.

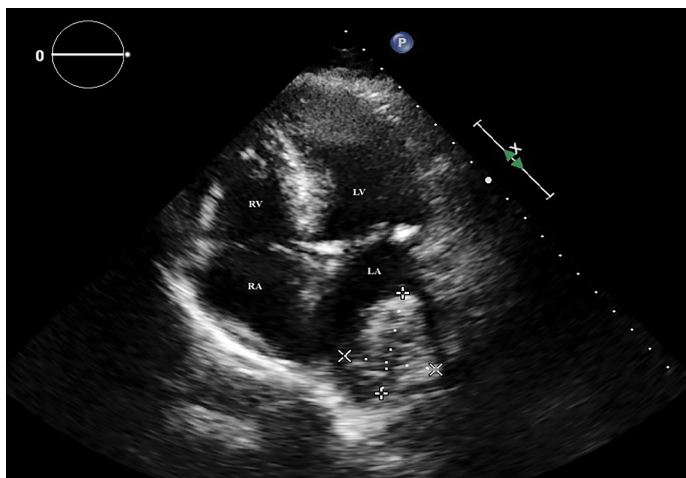


Figure 1. The apical four-chamber view demonstrating a heterogeneous mass within the left atrium

LA - left atrium, LV - left ventricle, RA - right atrium, RV - right ventricle

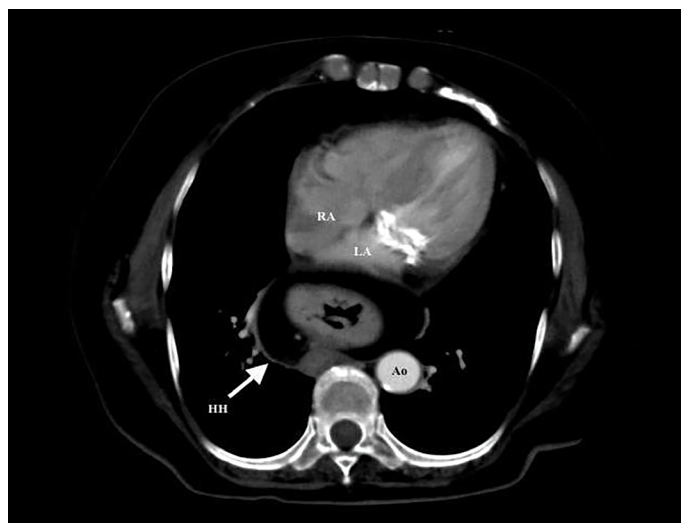


Figure 2. Axial view of thorax computed tomography depicting hiatal hernia posterior to the left atrium

AO - descending aorta, HH - hiatal hernia, LA - left atrium, RA - right atrium

HH is the herniation of elements of the abdominal cavity through the esophageal hiatus of the diaphragm such that it can mimic a left atrial mass on TTE by encroaching on the posterior aspect of LA. Some echocardiographic features may help the echocardiographer differentiate HH from other possible masses in the LA: (1) with proper angulation of the transducer, the echo density of HH extends beyond the margins of the atrium and (2) the oral indigestion of a carbonated beverage may result in the appearance of swirling echo densities in the mass (unfortunately, we were unable to test this). Nevertheless, cardiac CT is always useful for the better visualization of the mass, especially in a patient with stroke.

Informed consent: The author/s confirm that written consent for submission and publication of this case report including image(s) and associated text has been obtained from the patient.

Video 1. The apical four-chamber view demonstrating a suspicious large, well-circumscribed mass within the left atrium. Note the extension of the echo density beyond the margins of the atrium, with little angulation of the probe

Video 2. Transesophageal echocardiogram showing no mass in the left atrium

Mehmet Rasih Sonsöz*, **Mustafa Taner Gören***, **Zehra Buğra**
Department of Cardiology, İstanbul Faculty of Medicine, İstanbul University; İstanbul-Turkey

Address for Correspondence: Dr. Mehmet Rasih Sonsöz,
İstanbul Üniversitesi İstanbul Tıp Fakültesi,
Kardiyoloji Anabilim Dalı, İç Hastalıkları Binası,
Turgut Özal Cad. A Blok-1. Kat,
34093 Fatih, 34093
İstanbul-Türkiye
Phone: +90 212 414 20 00/31422
E-mail: mrsonsoz@gmail.com

©Copyright 2019 by Turkish Society of Cardiology - Available online
at www.anatoljcardiol.com

DOI:10.14744/AnatolJCardiol.2019.62678