

Partial detachment of mitral valve annuloplasty ring and evaluation with real-time 3D-transesophageal echocardiography

Mitral ring annuloplasty (MRA) is commonly considered as a treatment for those who require surgical revascularization due to coronary artery disease concomitant with moderate or severe mitral regurgitation (MR). In addition, the selection of an appropriate ring size is of importance in patients who undergo MRA. Moderate or severe MR may be an important issue with the use of partial detachment of small sized rings.

A 68-year-old male with a history of coronary artery bypass surgery 15 years and 5 years ago and MRA (29-mm Duran ring) for MR during the second surgery was referred to our clinic because of symptomatic severe MR. Transthoracic echocardiography demonstrated a dilated left ventricle with depressed systolic function and severe MR.

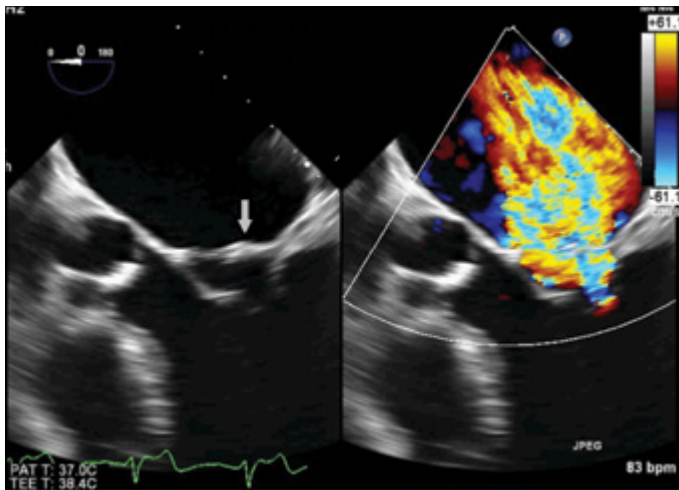


Figure 1. Transesophageal echocardiography demonstrates the mitral annuloplasty ring and severe mitral regurgitation from the middle segments of both leaflets (A2 and P2 segments) in the central 5C view

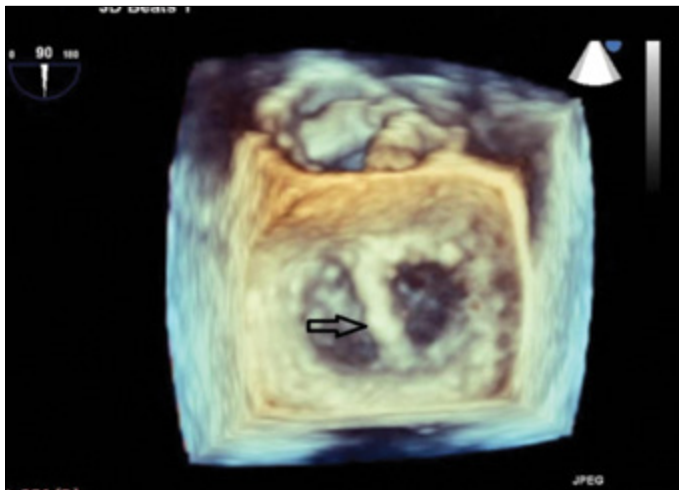


Figure 2. Three-dimensional transesophageal echocardiography demonstrates double orifice sign due to the dislocation of the mitral annuloplasty ring

Transesophageal echocardiography (TEE) demonstrated a severe MR from the middle scallops of both mitral leaflets (A2 and P2 segments). TEE also revealed that the previously implanted mitral annuloplasty ring (MAR) was detached from the anterior mitral leaflet and shifted to the central area of mitral valve (Fig. 1, 2). The 3D examination of TEE showed a double orifice sign due to the dislocation of the mitral annular ring (Video 1, 2).

The preferred type of therapy for patients with detachment of MAR is usually to perform mitral valve surgery once again. For this reason, choosing appropriate diagnosis methods and the detailed examination of the mitral valve have a crucial role. The partial detachment of MAR can not be visualized with 2D echocardiography; 3D echocardiography is more helpful for these situations. Especially in case of existence of MR in patients with MRA, a 3D-echocardiographic examination can provide more detailed information regarding the valvular structure.

Video 1. Transesophageal echocardiography demonstrates the mitral annular ring and severe mitral regurgitation from the middle segments of both leaflets (A2 and P2 segments) in central 5C view

Video 2. Real-time 3D-transesophageal echocardiography demonstrates double orifice sign due to the dislocation of the mitral annuloplasty ring

Mehmet Bilge, Yakup Alsancak¹, Sina Ali¹, Ayşe Saatçi Yaşar¹
Department of Cardiology, Yıldırım Beyazıt University; Ankara-Turkey
¹**Department of Cardiology, Atatürk Education and Research Hospital; Ankara-Turkey**

Address for Correspondence: Dr. Yakup Alsancak
 Atatürk Eğitim ve Araştırma Hastanesi,
 Kardiyoloji Bölümü, Bilkent, Ankara-Türkiye
 Phone: +90 312 291 25 25
 E-mail: dryakupalsancak@gmail.com

©Copyright 2015 by Turkish Society of Cardiology - Available online at www.anatoljcardiol.com
 DOI:10.5152/AnatolJCardiol.2015.6598

A giant coronary aneurysm on the right coronary artery in a 16-year-old patient

A coronary artery aneurysm is defined as when coronary arterial segments expand more than 1.5 times of a normal adjacent coronary artery. A giant coronary aneurysm is defined as an aneurysm with a diameter larger than 20 mm.

A 16-year-old boy from Syria known for using drugs, notably cocaine, was referred to our clinic. He has chest pain, cardiomegaly, and dextrocardia on his chest radiograph. His physical examination was normal, and his electrocardiogram demonstrated T-wave inversion in the precordial leads. His chest X-ray demonstrated dextrocardia and a normal cardiac silhouette. Two-dimensional echocardiography showed mildly dilated left-sided structures, and he had LV dysfunction in his heart. Sixty-four-detector multislice CT angiography was performed to evaluate the coronary arteries to make them better. The CT coronary angiogram revealed a giant aneurysm on the distal right coronary artery, which was 24 × 32 mm. Additionally, there was another small aneurysm measuring 6 × 4 mm. The small aneurysm was located next to the giant aneurysm (Fig. 1a-e).