

# A systematic review of 3-D printing in cardiovascular and cerebrovascular diseases

Zhonghua Sun, Shen-Yuan Lee<sup>1</sup>

Department of Medical Radiation Sciences, Curtin University; Western Australia-Australia

<sup>1</sup>Department of Medical Imaging and Radiological Science, Central Taiwan University of Science and Technology; Taichung-Taiwan

## ABSTRACT

**Objective:** The application of 3-D printing has been increasingly used in medicine, with research showing many applications in cardiovascular disease. This systematic review analyzes those studies published about the applications of 3-D printed, patient-specific models in cardiovascular and cerebrovascular diseases.

**Methods:** A search of PubMed/Medline and Scopus databases was performed to identify studies investigating the 3-D printing in cardiovascular and cerebrovascular diseases. Only studies based on patient's medical images were eligible for review, while reports on in vitro phantom or review articles were excluded.

**Results:** A total of 48 studies met selection criteria for inclusion in the review. A range of patient-specific 3-D printed models of different cardiovascular and cerebrovascular diseases were generated in these studies with most of them being developed using cardiac CT and MRI data, less commonly with 3-D invasive angiographic or echocardiographic images. The review of these studies showed high accuracy of 3-D printed, patient-specific models to represent complex anatomy of the cardiovascular and cerebrovascular system and depict various abnormalities, especially congenital heart diseases and valvular pathologies. Further, 3-D printing can serve as a useful education tool for both parents and clinicians, and a valuable tool for pre-surgical planning and simulation.

**Conclusion:** This systematic review shows that 3-D printed models based on medical imaging modalities can accurately replicate complex anatomical structures and pathologies of the cardiovascular and cerebrovascular system. 3-D printing is a useful tool for both education and surgical planning in these diseases. (*Anatol J Cardiol* 2017; 17: 423-35)

**Keywords:** 3-D printing, anatomy, cardiovascular disease, cerebrovascular disease, model, simulation

## Introduction

In recent years, three-dimensional (3-D) printing technologies have attracted increasing interests in medicine with various applications in medical fields, ranging from 3-D phantoms for simulation to bioprinting of organs (1–3). The life-sized 3-D printed models offer a realistic demonstration of complex 3-D anatomical structures and pathological changes associated with the cardiovascular system. With the use of the cardiac imaging data, 3-D printed models have been shown as useful tools for education and pre-surgical planning in different cardiovascular diseases (3–5). Despite rapid developments in 3-D printing techniques, most of the studies are based on individual case reports showing the feasibility of 3-D printing in depicting complex cardiovascular and cerebrovascular pathology; however, systematic review of these studies is lacking. The purpose of this sys-

tematic review is to evaluate the clinical value and applications of 3-D printing in cardiovascular and cerebrovascular diseases.

## Methods

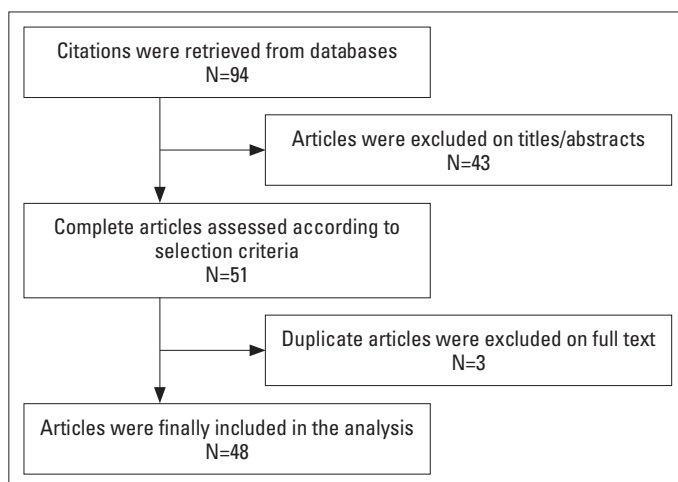
This review was performed in accordance with the PRISMA guidelines (6). PubMed/Medline and Scopus databases were searched until November 30, 2016 using the following search keywords: 3-D printing and cardiac disease/cardiovascular disease/congenital heart disease/aortic or cerebrovascular disease. Studies were eligible for inclusion in the review if they evaluated 3-D printed models based on in vivo patient imaging data. Studies using in vitro phantom experiments or review articles were excluded. References were searched and evaluated by two independent reviewers to determine the eligibility of the studies with disagreements resolved by consensus.

**Address for correspondence:** Professor Zhonghua Sun, Department of Medical Radiation Sciences School of Science, Curtin University, GPO Box, U1987, Perth, Western Australia 6845-Australia  
Phone: +61-8-9266 7509 Fax: +61-8-9266 2377 E-mail: z.sun@curtin.edu.au

**Accepted Date:** 17.02.2017 **Available Online Date:** 10.04.2017

©Copyright 2017 by Turkish Society of Cardiology - Available online at [www.anatoljcardiol.com](http://www.anatoljcardiol.com)  
DOI:10.14744/AnatolJCardiol.2017.7464





**Figure 1.** Flow chart showing strategy for identifying the eligible studies in this review

Two reviewers independently screened the titles and abstracts of all identified references from the search strategy. Data were extracted from individual studies with a focus on the following details: year of publication, number of cases, imaging techniques used for 3-D printing, and key research findings reported in each study. The two reviewers repeatedly extracted these details to avoid intra-observer variability. Also, other details such as materials used for 3-D printing, model properties, and cost associated with 3-D printing were also extracted if they were available in the studies.

## Results

A total of 94 hits were initially identified with 43 articles excluded because they did not meet the inclusion criteria. Of 51 eligible studies (7–57), three studies were further excluded due to duplicate publications from the same research groups (55–57), thus leading to a total of 48 studies included in the review. Figure 1 is the flow chart showing search strategy to identify eligible studies.

Of these 48 studies, 20 of them (42%) were based on individual case reports to generate 3-D printed models, while 24 studies were based on a number of cases ranging from 2 to 20 selected patients with different cardiovascular and cerebrovascular diseases. The remaining four studies focused on surveying the opinion on the usefulness of 3-D printed models by pediatric physicians, parents of pediatric patients, cardiac nurses, and medical students, respectively (10, 11, 14, 24). Table 1 shows study characteristics of 3-D printing in cardiovascular and cerebrovascular diseases as reported in these eligible studies.

Cardiac computed tomography (CT) is the most common imaging modality with images used for generating 3-D printed models in 24 studies. Cardiac magnetic resonance imaging (MRI) was used in 8 studies, and either data from cardiac CT or MRI were used for 3-D printing in another 8 studies. 3-D printed models were based on 3-D digital subtraction angiography or rotational angiography images in 4 studies and 3-D echocardiographic images in another three studies. In the remaining study, hybrid

3-D imaging was applied with the use of 3-D echocardiography and cardiac CT images to generate 3-D printed models (19).

Different materials and a range of 3-D printers were used for 3-D printing and were reported in 29 studies, while in the remaining studies, the information was not available. Mechanical properties of the materials used for 3-D printing were only provided in two studies (43, 54), with details of tensile strength and tensile modulus being provided in correspondence to different materials. Table 2 shows details of the materials and 3-D printers as reported in these studies. The cost associated with manufacturing 3-D printed models was only provided in 12 studies, with a wide range of costs being reported depending on the size and complexity of the models, as shown in Table 2.

The clinical applications of patient-specific 3-D printed models are overall positive with results showing high accuracy in replicating complex anatomy of cardiovascular and cerebrovascular pathologies (in particular, congenital heart disease).

## Discussion

This review shows that patient-specific 3-D printed models created from standard imaging modalities show high accuracy for replicating complex cardiovascular and cerebrovascular structures with most of the applications in congenital heart diseases and valvular pathologies. 3-D printed models have been shown to improve diagnosis and enhance physicians' knowledge and understanding of cardiovascular pathologies, in particular, congenital heart disease. Furthermore, 3-D printed models are suitable for pre-surgical planning and minimally invasive procedures as shown in more than half of the studies in this review.

Findings of the applications of 3-D printing in cardiovascular and cerebrovascular diseases can be summarized into the following three main areas according to this review: first, 3-D patient-specific models were shown to represent complex anatomy of the cardiovascular and cerebrovascular system and depict various pathologies with high accuracy. Excellent agreement or correlation was found between 3-D printed models and 2-D/3-D pre-3-D printing images (Fig. 2) (12, 16, 17, 32, 37, 40, 48). Olivieri et al. (32) compared 3-D printed model measurements with 2-D echocardiographic images in 9 patients with congenital heart disease, and their results showed high correlation between these two methods, with 3-D printed model having accuracy of less than 1 mm (the mean absolute error between 2-D images and 3-D printing was  $0.4 \pm 0.9$  mm) (32). This is confirmed by another study on 3-D printing accuracy in aortic disease. Sun and Squelch compared measurements taken at six different anatomical locations of ascending and descending aorta for pre-3-D printing CT images of an aortic aneurysm and aortic dissection, 3-D printed models and post-3-D printing images with measurement differences were less than 0.8 mm (49). This indicates the reliability of using 3-D printed models for the diagnostic assessment of cardiovascular disease.

**Table 1. Study characteristics of using 3-D printing in cardiovascular and cerebrovascular disease with individual cases**

First author, et al.	Year of publication	Imaging data used for 3-D printing	Study design, no. of participants, and age range	Key findings
Anderson et al. (7)	2014	3-D DSA images for 3-D models, 4-D phase contrast MRI for flow and CFD analysis	Six cases of cerebral aneurysms (age, not available)	3-D printed models replicate cerebral aneurysms with simulation of flow patterns and hemodynamic changes as confirmed by phase contrast MRI images
Anwar et al. (8)	2016	MDCT with high-pitch mode or cardiac MRI images	Nine cases (4 months to 36 years) with complex congenital heart disease	3-D printed models precisely demonstrate complex cardiac anatomy, plan surgical procedures, and teach trainees and patients
Bartel et al. (9)	2016	MDCT images	A 48-year-old male with atrial septal defect	3-D printed model assists accurate device deployment and procedural optimization
Biglino et al. (10)	2016	Cardiac MRI images	100 nurses (65 pediatric and 35 adult) were presented with a range of 3-D printed models for their views on the usefulness of the 3-D models through questionnaires	Patient-specific, 3-D printed models of congenital heart disease are found to be useful in training adult and pediatric cardiac nurses by demonstrating complex cardiac anatomy
Biglino et al. (11)	2015	MDCT or MRI images	Questionnaires were distributed to 97 parents of pediatric patients with congenital heart disease and 2 cardiologists  Model group: 45 participants with use of 3-D patient-specific model during each visit.  Control group: 52 participants with no model used during consultation	3-D patient-specific models were rated very useful by both patients and cardiologists  3-D printed models improved communication between parents and cardiologists  Parental knowledge or understanding of their child's condition was not improved with use of 3-D printed models
Binder et al. (12)	1999	3-D echocardiographic images	13 patients (median age, 50 years; range 28 to 72 years) underwent transesophageal 3-D echocardiography  12 were suitable for 3-D printing with 24 models printed (6 normal mitral valve, 18 different mitral valve pathologies)	3-D printed models allow for accurate depiction of mitral valve anatomy and pathology  Excellent agreement was found for measurement of volume and maximal dimensions between 3-D models and in vitro phantoms
Canstein et al. (13)	2008	3-D MRA. Models from patients 2 and 3 were used for in vitro 4-D MRI, while model from patient 3 was used for CFD simulation	Three cases (1 with severe kinking of descending aorta and small aneurysm in right subclavian artery, 2 with normal cases)	3-D printing in combination with MRA and 4-D MRI enables analysis of flow hemodynamics in realistic model systems
Costello et al. (14)	2015	MRI images	Questionnaires were distributed to 23 pediatric resident physicians  3-D printed models with five common ventricular septal defect diseases were created and used in a simulation-based curriculum	Using 3-D printed models was found to significantly improve pediatric resident physicians' knowledge and understanding of congenital heart disease ( $P<0.05$ )  3-D printing technology serves as a feasible education and simulation tool in the clinical setting
Dankowski et al. (15)	2014	MDCT images	A 41-year-old male patient with heart failure	The 3-D model was used to quantify the LV end-diastolic diameter and LV height with high accuracy  3-D printed model can be used to plan individualized procedures and optimize the implantation of percutaneous annuloplasty system

Continued →

**Continued Table 1. Study characteristics of using 3-D printing in cardiovascular and cerebrovascular disease with individual cases**

First author, et al.	Year of publication	Imaging data used for 3-D printing	Study design, no. of participants, and age range	Key findings
D'Urso et al. (16)	1999	MDCT and MRI images	16 cases with 15 having cerebral aneurysms and 1 with cerebral arteriovenous malformation	3-D models replicate anatomical details accurately 3-D models enhance surgeon's understanding of complex pathology and assist planning of the surgical approach
Farooqi et al. (17)	2016	Cardiac MRI (5 MRA, 1 3-D SSFP)	Six patients (median age, 6.5 years; range 2 to 29 years) with complex double outlet right ventricle	3-D models demonstrate intracardiac structures from different views, thus improving the understanding of real anatomic relationships. There is excellent correlation for measurements of aortic annulus diameters, VSD diameters, and RV long axis between 3-D models and source CMR images
Gallo et al. (18)	2016	MDCT images	A 79-year-old patient with severe comorbidities	3-D printed models serve as useful tools to plan complex transcatheter valve implantation
Gosnell et al. (19)	2016	Hybrid 3-D imaging with use of 3-D transesophageal echocardiography and MDCT images	A 55-year-old male with congenitally-corrected transposition of the great vessels (L-TGA)	3-D printed models derived from multiple imaging modalities are feasible to accurately demonstrate the morphology of congenital heart disease
Greil et al. (20)	2007	MDCT and cardiac MRI images	Five patients (median age, 12.6 years; range 41 days to 21 years) with congenital heart disease	3-D printed models derived from CT or MRI images accurately represent cardiac pathology 3-D printed models may serve as teaching and preoperative planning purpose
Itagaki et al. (21)	2015	MDCT images	A 62-year-old female with multiple asymptomatic splenic artery aneurysms	3-D printed models with accurate representation of vascular anatomy are feasible and affordable
Jacobs et al. (22)	2008	MDCT and cardiac MRI images	Three cases (1 with malignant tumor, 2 with ventricular aneurysms)	3-D printed models may improve surgical outcome by improving preoperative planning and intraoperative orientation of risk structures and target tissue
Kimura et al. (23)	2009	MDCT images	8 prospective cases (median age, 63.5 years; range 39 to 81 years) and 3 retrospective cases with cerebral aneurysms	3-D models help neurosurgeons' understanding of 3-D relationship of vascular anatomy before and during surgical procedures 3-D models enhance confidence for inexperienced surgeons during live surgery
Lim et al. (24)	2016	MDCT images	52 participants (first year medical students): 18 used cadaveric materials, 16 used 3-D printed heart models, and 18 used combined materials (a combination of cadaveric materials and 3-D models)	Significant improvement in post-test scores ( $P=0.003$ ) was found in the group that used 3-D printed models when compared to the other two groups 3-D printed models serve as appropriate supplements to cadaver-based curriculum in medical education
Little et al. (25)	2016	MDCT images	A 62-year-old man with severe mitral valve regurgitation with restricted leaflet coaptation and perforation of the posterior leaflet	Patient-specific 3-D printed model assists mitral valve intervention by facilitating selection and sizing of an occluder device
Maragiannis et al. (26)	2015	MDCT images	Eight (median age, 82.5 years; range 55 to 92 years) patients with severe aortic stenosis	3-D printed models of patient-specific aortic valve and root anatomy and functional properties are feasible with accurate replication of these features

Continued →

**Continued Table 1. Study characteristics of using 3-D printing in cardiovascular and cerebrovascular disease with individual cases**

First author, et al.	Year of publication	Imaging data used for 3-D printing	Study design, no. of participants, and age range	Key findings
Mashiko et al. (27)	2015	MDCT images	20 patients (median age, 63 years; range 47 to 75 years) with cerebral aneurysms.  Clipping was performed in 12 patients, while clipping was not done in the remaining 8 patients  12 surgeons responded to the questionnaire after the clipping operation  6 junior surgeons learned how to clip using the 3-D printed models	3-D printed hollow elastic model is considered useful for understanding of 3-D aneurysm structure  The surgeon's postoperative assessment was overall favorable  3-D printed models provide surgeons with a better 3-D understanding than with a simulated 3-D display on a flat computer screen
Mottl-Link et al. (28)	2008	3-D MRI images	A 24-year-old patient with complex congenital heart malformation (pulmonary atresia, large ventricular septal defect, atrial septal defect, tricuspid regurgitation, and dextrocardia)	3-D printed physical models improve orientation at an open heart by demonstrating anatomical structures which could not be intraoperatively obtained  3-D printing may assist high-risk correction procedures in patients with complex congenital heart disease
Namba et al. (29)	2015	3-D rotational angiographic images	10 patients (median age 59.5 years; range 45 to 71 years) with cerebral aneurysm. All patients were treated with endovascular procedure  Preplanned microcatheter shape was tested on 3-D printed models prior to endovascular treatment	3-D printing allows accurate and stable catheter design, thus determining optimal microcatheter shape for coiling an aneurysm before the procedure
Ngan et al. (30)	2006	MDCT images	Six patients (6 months to 2 years 6 months) with pulmonary atresia with ventricular septal defect and major aorto-pulmonary collateral arteries (MAPCAs)	3-D printed models accurately (>90%) represent MAPCAs which were identified during surgery and conventional angiography  3-D printed models were found by surgeons to be useful in preoperative planning
Noecker et al. (31)	2006	MDCT images	11 patients (median age, 3 years; range 2 days to 13 years) with and without congenital heart disease  12 models with 3 normal and 9 different congenital heart diseases showing cardiac and thoracic structures	3-D printed models replicate cardiac structures and congenital heart diseases with high accuracy  3-D printing technique has the potential to assist preoperative planning by demonstrating precise 3-D relationships between anatomic structures
Olivieri et al. (32)	2015	3-D echocardiography images	Nine patients with congenital heart disease (eight with ventricular septal defects and one with three periprosthetic aortic valve leaks)	3-D printed models derived from 3-D echocardiographic datasets show high accuracy in replicating congenital heart disease with excellent correlation between standard 2-D and 3-D model measurements
Olivieri et al. (33)	2014	MDCT images	A 30-year-old man with pulmonary venous baffle obstruction	3-D printed model assists planning the interventional approach by increasing procedural efficiency and reducing procedural complications

Continued →



**Continued Table 1. Study characteristics of using 3-D printing in cardiovascular and cerebrovascular disease with individual cases**

First author, et al.	Year of publication	Imaging data used for 3-D printing	Study design, no. of participants, and age range	Key findings
O'Neill et al. (34)	2015	MDCT images	A 57-year-old patient with severe mitral valve regurgitation post-mitral ring placement	3-D printed model aids in selection of transcatheter valve and guides periprocedural and multimodality planning for transcatheter caval valve implantation
Otton et al. (35)	2015	MDCT images	A 74-year-old man with paroxysmal atrial fibrillation	3-D printing has potential clinical utility for both device (left atrial occlusion device) sizing and avoiding procedural complications
Poterucha et al. (36)	2014	3-D rotational angiographic images	A 15-year-old girl with combined neopulmonary stenosis and regurgitation	3-D printed model represents a novel and valuable tool for patient and trainee education
Ripley et al. (37)	2016	MDCT images	16 patients (median age, 85 years; range 69 to 91 years). 9 had paravalvular aortic regurgitation (PAR) and 7 were control patients	Excellent agreement was reached between 3-D models and 2-D images for annulus measurements 3-D printing as a novel technique may complement traditional methods to predict and avoid PAR or other complications
Ryan et al. (38)	2015	MDCT images	One day of age with Tetralogy of Fallot, pulmonary stenosis, and multiple aorto-pulmonary collateral arteries	3-D printing provides significant advantages in preoperative and periprocedural planning of complex cardiovascular disease
Salloum et al. (39)	2016	MDCT images	A 63-year-old asymptomatic man with 3-cm aneurysm of the celiac trunk	3-D printing allows optimization of the choice of operative approach 3-D printing combined with surgical robot represents an innovative, minimally invasive technique
Samuel et al. (40)	2015	3-D echocardiography images	One selected case with atrial septal defect for 3-D printing	3-D printed models using 3-D echocardiography imaging are feasible and maybe potentially valuable in surgical or interventional cases
Schievano et al. (41)	2007	MRI images	12 patients (median age, 17 years; range 9–39 years) who had been referred for possible percutaneous pulmonary valve implantation (PPVI)	Excellent correlation was found between dimensional measurements on 3-D MRI images and 3-D printed models ( $r=0.97$ , $P<0.001$ ) 3-D printing enables complete appreciation of anatomy of right ventricular outflow tract and pulmonary trunk, thus, assisting selection of patients for PPVI more accurately
Schievano et al. (42)	2010	MDCT images	A 42-year-old male with severe pulmonary insufficiency	Percutaneous pulmonary valve can be safely implanted in a dilated pulmonary trunk with aid of a patient-specific 3-D printed device
Schmauss et al. (43)	2015	MDCT or MRI images	Eight patients (3 months to 81 years): 4 pediatric cases with congenital heart disease, while the other 4 were adult patients with different cardiac diseases	3-D printed models are shown to be feasible for perioperative planning and simulation in various complex pediatric and adult cardiac diseases, as well as in interventional cardiology
Shiraishi et al. (44)	2010	MDCT images	Eight pediatric patients (4 days to 4 years) with congenital heart disease	3-D printed biomedical models have been shown to be a promising technique for preoperative simulation of surgical procedures in patients with congenital heart disease

Continued →

**Continued Table 1. Study characteristics of using 3-D printing in cardiovascular and cerebrovascular disease with individual cases**

First author, et al.	Year of publication	Imaging data used for 3-D printing	Study design, no. of participants, and age range	Key findings
Sodian et al. (45)	2007	MDCT and MRI images	Two pediatric patients with 1 diagnosed with aberrant retroesophageal left subclavian artery and right aortic arch, and another with ventricular septal defect	3-D printed models are feasible for demonstrating complex cardiovascular pathology
Sodian et al. (46)	2008	MDCT and MRI images	2 pediatric patients (2 and 14 years) with univentricular heart	It is feasible to produce 3-D printed models of the patients with univentricular hearts. The physical models offer practical advantages for clinicians and researchers to better understand complex cardiac anatomy and pathology
Sodian et al. (47)	2008	MDCT images	An 81-year-old woman who had previous coronary artery bypass grafting developed aortic valve stenosis	3-D printed models improve surgeon's comprehension of 3-D cardiovascular anatomy and aid in development of optimal surgical approach
Sodian et al. (48)	2009	MDCT images	A 50-year-old patient with HIV infection who developed pseudoaneurysm after aortic arch replacement due to type A aortic dissection	3-D printed models prove to be useful for interventionalists and surgeons treating complex cardiac pathology
Sun et al. (49)	2016	MDCT images	Three patients with aortic dissection and aortic aneurysm	3-D printed models showed high accuracy when compared to CT angiography Aortic dissection and intimal flap are replicated
Tam et al. (50)	2013	MDCT images	A 75-year-old man with infrarenal abdominal aortic aneurysm	3-D printed models facilitate visualization of complex anatomic structures and assist in planning of surgical procedures
Valverde et al. (51)	2015	MRI images	A 1.5-year-old boy with complex congenital heart disease (transposition of the great arteries, ventricular septal defect, and pulmonary stenosis)	3-D printed models allow the surgeons to better evaluate the location and dimensions of cardiovascular pathology, and assist in planning cardiac surgery in patients with complex congenital heart disease
Valverde et al. (52)	2015	MRI images	A 15-year-old boy with hypoplastic aortic arch	3-D printed models are shown to accurately replicate anatomy with high correlation between 3-D models and MRI and angiographic images 3-D printed models assist in planning endovascular stenting procedures
Vranicar et al. (53)	2008	MDCT images	12 patients (median age, 8 years; range 19 days to 29 years). 9 aortic coarctation, 3 vascular ring Models were compared to catheterization and surgical findings	Realistic 3-D printed models can accurately demonstrate complex aortic pathology and provide important additional information 3-D printed models may be useful teaching tools for parents and students
Wurm et al. (54)	2011	3-D rotational angiographic images	Normal cerebral vascular anatomy with aneurysm created during stereolithography process	3-D printed models offer great opportunity for preoperative rehearsal and neurosurgical training and assessment

CFD - computational fluid dynamics; CMR - cardiac magnetic resonance; MAPCAs - major aorto-pulmonary collateral arteries; MDCT - multidetector computed tomography; LV - left ventricle; MRI - magnetic resonance imaging; PAV - paravalvular aortic regurgitation; PPVI - percutaneous pulmonary valve implantation; RV - right ventricle; SSFP - steady state free precession; TGA - transportation of the great arteries; VSD - ventricular septal defect

**Table 2. Type of materials and 3-D printers used for 3-D printing in cardiovascular disease**

Studies	Materials used for 3-D printing and associated costs	3-D printers
Anderson et al. (7)	Poly lactide resin filaments	Makerbot Replicator, 2 <sup>nd</sup> generation 3-D printer
Anwar et al. (8)	N/A	N/A
Bartel et al. (9)	N/A	Materialise
Biglino et al. (10)	N/A	N/A
Biglino et al. (11)	White nylon	EOSINT P360
Binder et al. (12)	Polyacrylic polymer	Stereolithography (SLA 250/30A)
Canstein et al. (13)	Photopolymer	Polyjet Eden 330
Costello et al. (14)	Polyjet	Objet 500 Connex 3D printer
Dankowski et al. (15)	Photopolymer resin	Commercial Stereolithography machine
D'Urso et al. (16)	Resin monomer USD 300	Stereolithography machine
Farooqi et al. (17)	N/A	N/A
Gallo et al. (18)	N/A	N/A
Gosnell et al. (19)	Flex material	HeartPrint
Greil et al. (20)	Polyamide power	Laser sintering machine Eosint P 385
Itagaki et al. (21)	White nylon Solid luminal model: USD: 50.34 Hollow vessel model: USD: 235.03	Shapeways
Jacobs et al. (22)	Plaster power	N/A
Kimura et al. (23)	Rubber-like polymer (Tango Plus) USD 300–400	Rapid prototyping machine
Lim et al. (24)	N/A	N/A
Little et al. (25)	N/A	N/A
Maragiannis et al. (26)	Vero White Plus for rigid material TangoPlus for soft tissue structure	Objet 260 Connex 3-D Printer (Stratasys)
Mashiko et al. (27)	ABS (acrylonitrile-butadiene-styrene) resin JPY: 90–290	OPT 3D printer
Mottl-Link et al. (28)	Plaster power USD: 364	ZPrinter 310
Namba et al. (29)	ABS resin JPY: 150	OPT 3-D printer
Ngan et al. (30)	Solid acrylic or plastic material	Stratasys Prodigy Plus or In Vision si2 3-D printer
Noecker et al. (31)	Starch-based power for rigid models Polyurethane and silicone rubber for flexible models	ZPrinter 310
Olivieri et al. (32)	N/A	Objet500 Connex Polyjet Printer (Stratasys)
Olivieri et al. (33)	N/A	Objet500 Connex Polyjet Printer (Stratasys)
O'Neill et al. (34)	N/A	N/A
Otton et al. (35)	Rubber-like material to simulate atrial mechanical properties	Objet500 Connex Printer (Stratasys)
Poterucha et al. (36)	N/A	Objet350 Connex Printer (Stratasys)
Ripley et al. (37)	Clear flexible resin	Form 1 Plus 3-D printer
Ryan et al. (38)	N/A	N/A
Salloum et al. (39)	N/A Euro: 400	Dimension 1200es Printer (Stratasys)
Samuel et al. (40)	Flex material	Materialise HeartPrint
Schievano et al. (41)	Thermoplastic resin	P1500 polyester

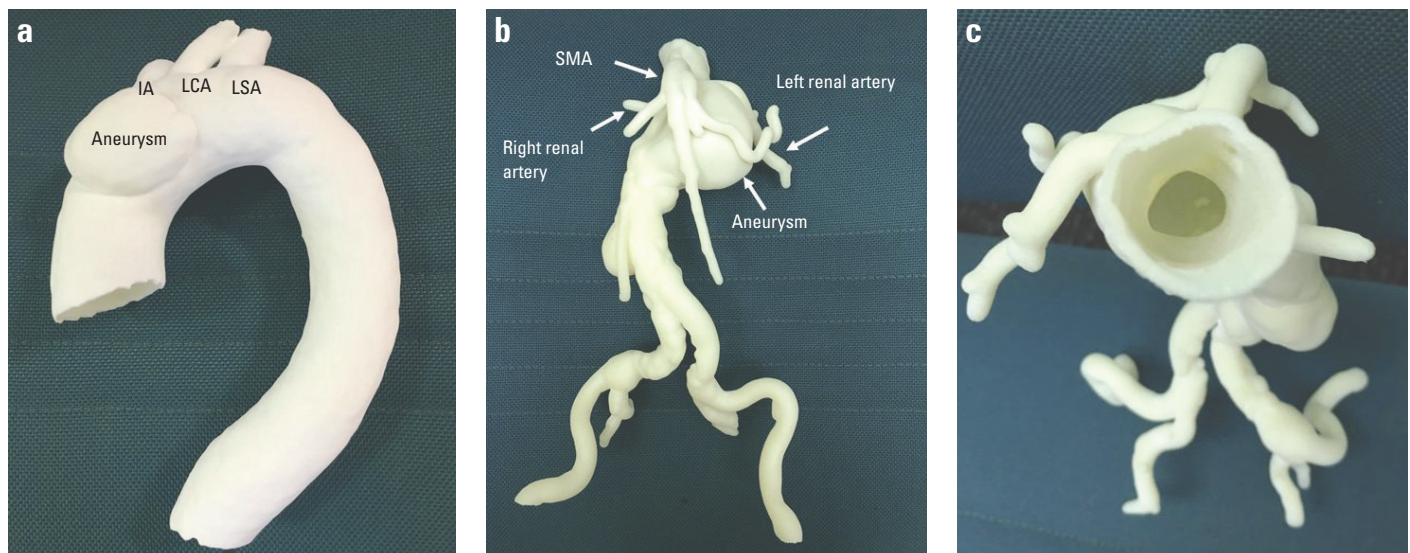
Continued →



**Continued Table 2. Type of materials and 3-D printers used for 3-D printing in cardiovascular disease**

Studies	Materials used for 3-D printing and associated costs	3-D printers
Schievano et al. (42)	N/A	N/A
Schmauss et al. (43)	Starch/cellulose powder. Elastomeric urethane resin was used for infiltration after printing. Euro: 200 to 400	Z <sup>TM</sup> 510 Printer
Shiraishi et al. (44)	Solid epoxy and rubber-like urethane Solid epoxy: tensile strength: =78MPa, tensile modulus=2.8 GPa Rubber-like urethane: tensile strength=3.8 MPa, tensile modulus=0.01 GPa	Stereolithography machine (JMC)
Sodian et al. (45)	N/A	Stereolithography machine (ZCorp)
Sodian et al. (46)	N/A	Stereolithography machine (ZCorp)
Sodian et al. (47)	N/A	Stereolithography machine (ZCorp)
Sodian et al. (48)	N/A	Stereolithography machine (ZCorp)
Sun et al. (49)	Nylon power USD: 122	Shapeways
Tam et al. (50)	Thermoplastic polylactic acid USD: 150–500	Orcabot printer
Valverde et al. (51)	Polylactic acid USD: 350	Stereolithography machine
Valverde et al. (52)	Polylactic acid and flexible polymer	Stereolithography machine
Vranicar et al. (53)	Photopolymer	Stereolithographic laser printer
Wurm et al. (54)	Epoxy photopolymer with a tensile strength of around 50 MPa Euro: 2000	Model SLA-3500 for STL model Objet 500 Connex 3-D Printer for 3-D model

N/A - not available

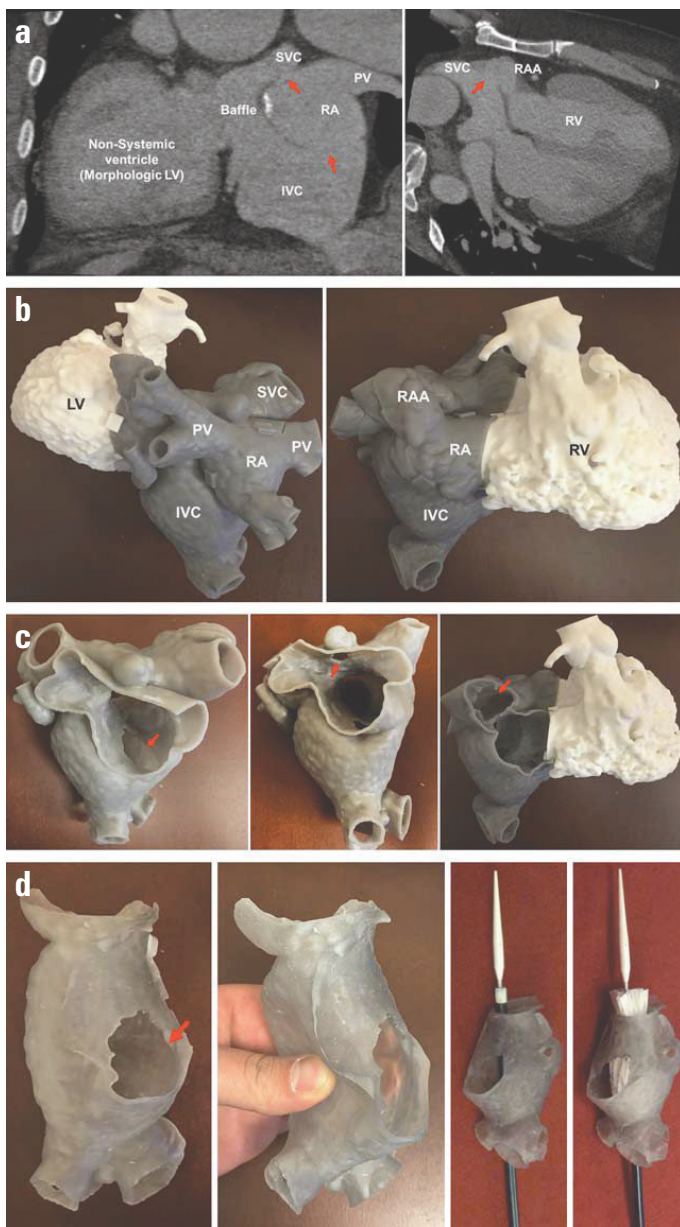


**Figure 2.** 3-D printed models of aortic aneurysms. (a) 3-D printed patient-specific model shows an aneurysm involving the ascending aorta. (b) Anterior view of a 3-D printed model with an abdominal aortic aneurysm. (c) Superior view of the same 3-D printed model as shown in B showing the hollow structure of the abdominal aorta

IA - innominate artery; LCA - left common carotid artery; LSA - left subclavian artery; SMA - superior mesenteric artery

High diagnostic accuracy of 3-D printing in valvular diseases was also reported in some studies (26–28, 34, 37, 41, 47). Schievano et al. (41) used MR data from 12 patients with the pulmonary valvular disease to create 3-D printed rigid models with results showing accuracy in demonstrating the 3-D anatomy of the right ventricu-

lar outflow tract and pulmonary trunk. Further, 3-D printed models were more accurate than MRI images in selecting patients for percutaneous pulmonary valve implantation (41). Ripley et al. (37) in their recent report demonstrated the usefulness of 3-D printed models for assessment of aortic roots and implanted aortic valves



**Figure 3.** Models for planning and simulation of stent deployment for Mustard baffle revision in a 45-year-old man with a history of complete transposition of great vessels. (a) Delayed venous phase CT demonstrating a large defect between the IVC and the pulmonary venous pathways at the rightward aspect of the baffle, a smaller defect between the SVC and the pulmonary venous pathways, and an intermediate-sized defect between the baffle and the right atrial appendage (red arrows). (b) 3-D printed model of the baffle designed as a fictitious wall around the blood pool (printed in gray) and including the ventricles (printed in white) for spatial orientation in this difficult case. (c) Removable ventricles and cut-out window of the wall of the pulmonary venous pathway/right atrium demonstrate the superior small and inferior large baffle defect (red arrows) and cut-out window of the right atrial wall demonstrates the third baffle defect communicating with the right atrial appendage. (d) A segment of the baffle was also printed in flexible material and used to simulate stent graft deployment to ensure an adequate proximal sealing zone

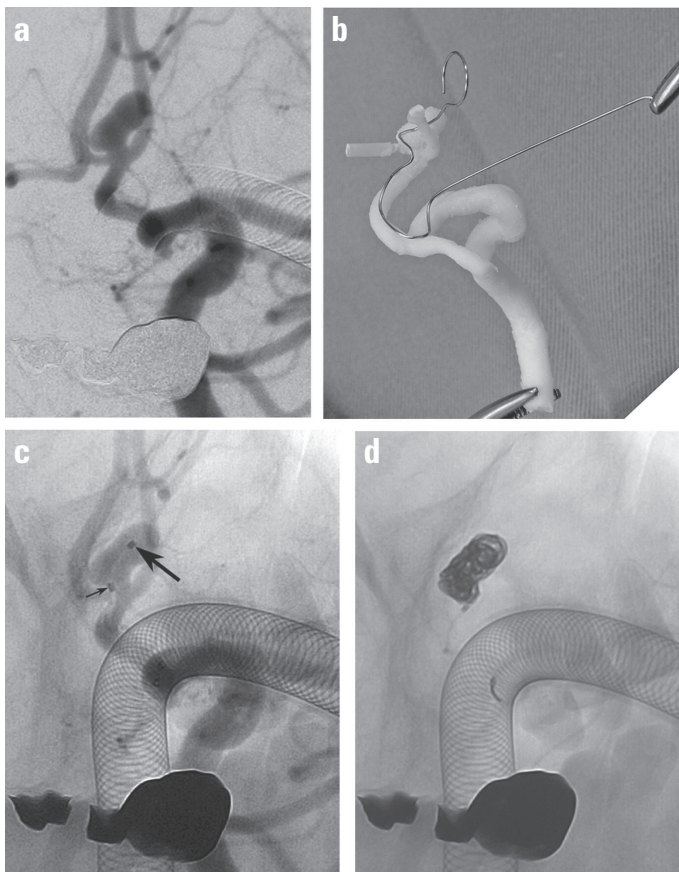
IVC - indicates inferior vena cava; LV - left ventricle; PV - pulmonary vein; RA - right atrium; RAA - right atrial appendage; RV - right ventricle; SVC - superior vena cava. Reprinted with permission from Giannopoulos et al. (4)

based on CT data from 16 patients. Excellent agreement was found between 3-D models and 2-D CT data for annulus measurements with mean difference less than 0.4 mm. 3-D printed models also showed high accuracy within 0.1 mm of designed dimensions in the valve prostheses (37). Maragiannis et al. (26) extended the applications of 3-D printing to aortic valve disease using multi material 3-D printed models. Eight patient-specific 3-D models of severe aortic stenosis were created with accurate replication of both anatomic and functional properties of aortic valve stenosis. Each model was assessed using 2-D echocardiography for peak flow velocity, transvalvular gradient, and aortic valve area, and it was found to be in accordance with the clinical Doppler study (26). This further confirms that 3-D printed models represent a novel technique to study functional characteristics of valvular diseases.

Second, 3-D printing can serve as a useful education tool for both parents and clinicians, healthcare professionals, and medical students. Biglino et al. (11) investigated the benefit of 3-D patient-specific models in the doctor-patient communication by comparing the model group with a control group. Forty-five participants in the model group were presented with 3-D printed patient-specific models of their children's heart diseases, while 52 participants (parents of pediatric patients) in the control group did not have any model during the consultation. 3-D printed models were scored very useful by both parents and cardiologists, with improved communication between parents and cardiologists who dealt with congenital heart disease (11). Another recent study by the same research group reported the usefulness of 3-D printed models for training adult and pediatric cardiac nurses (10). Similarly, Costello et al. (14) reported significant improvement of pediatric resident physician's knowledge and understanding of congenital heart disease through a questionnaire study. Using 3-D printed models of ventricular septal defects, pediatric residents' ability to manage postoperative complications in patients with ventricular septal defects was also improved (14). In a recently published randomized control trial, 3-D printed models have been shown to significantly improve medical students' knowledge in learning external cardiac anatomy when compared to cadaver-based curriculum (24). Studies based on case reports have also shown that 3-D printed models improve surgeons' understanding of complex cardiac disease (20, 23, 27, 28, 31, 45-47).

Third, 3-D printing is regarded as a valuable tool for pre-surgical planning and simulation of cardiovascular and cerebrovascular diseases (Fig. 3). Mashiko et al. (27) analyzed the value of 3-D printing in 20 patients with cerebral aneurysms. Clipping surgery was performed in 12 patients while no clipping was done in eight patients. Twelve experienced surgeons were asked to respond to the questionnaire after the operation, while another six junior surgeons who had never had any experience performing clipping surgery were invited to learn how to clip an aneurysm using 3-D printed models. Qualitative and quantitative assessments were overall favorable according to surgeon responses, confirming the advantages of 3-D printed models over conventional flat computer screens (27). Also, 3-D printing techniques assists the





**Figure 4.** (a) Left internal carotid artery (ICA) angiogram in left oblique view demonstrates an aneurysm overriding the anterior communicating artery. (b) Preplanning of the shaping mandrel. The curves of the ICA and anterior cerebral artery, in addition to the aneurysm axis, are reproduced on the mandrel. Two types of microcatheter tip shapes were formed by use of the same mandrel by adjusting the insertion of the microcatheter. (c) No subtracted left ICA angiogram in left oblique view after advancement of the predetermined microcatheters. Note that the proximal catheter (small arrow) is pointing to the right and the distal catheter (large arrow) to the left as planned. (d) At the end of the coiling, the tip of the distal microcatheter is stably pointing toward the aneurysm. The proximal microcatheter has been withdrawn during the procedure. Reprinted with permission from Namba et al. (29)

design of catheter devices before the operating procedure. This is confirmed by a recent study conducted by Namba et al. (29). Authors used 3-D printed hollow models of a cerebral aneurysm to verify the preplanned shape of microcatheter, with successful catheterization in both 3-D printed models and patient's intracranial aneurysm (Fig. 4). Their results based on 10 cases with cerebral aneurysms contribute to determining a patient-specific and optimal microcatheter shape, which is essential for coiling an aneurysm preoperatively. Other case reports supported these findings by showing the potential clinical value of using 3-D printing for assisting/guiding interventional procedures, selecting appropriate device sizes, and reducing procedural complications (18, 22, 25, 28–30, 33–35, 37, 39, 41, 43, 47, 52, 54).

The recent growth and development of 3-D printing have enabled the generation of 3-D models of complex anatomy with high resolution and accuracy in depicting both cardiovascular/cerebro-

vascular anatomy and pathology. The expanded applications of this technology in cardiovascular and cerebrovascular disease allow for rapid generation of 3-D complex anatomical structures from medical imaging datasets, such as CT, MRI or echocardiography data of patients, although cardiac CT and MRI are the most commonly used imaging modalities (1–4). This is confirmed in this review as 3-D printed models have shown promising results in these studies with high accuracy of replicating cardiovascular and cerebrovascular diseases, in particular, its applications in congenital heart disease as shown in the studies discussed in this review.

Although 3-D printing holds great promise in cardiovascular medicine, the application of this technology in routine clinical practice is still in its infancy (4, 5). There are some limitations that exist in the current literature on 3-D printing. First, as shown in this review, most of the current studies are based on isolated case reports, indicating the necessity of further studies with inclusion of more cases based on large cohort prospective studies. Second, materials used for 3-D printing in most of the studies do not match the true mechanical properties of cardiovascular and cerebrovascular anatomies in terms of the true elastic modulus of arterial wall or cardiac chambers. Only two studies provided detailed information on this aspect. Thus, this represents a major limitation of the current 3-D printed models. Future research is desirable to develop 3-D printed models with appropriate materials reflecting mechanical properties of human anatomy and pathology, such as deformability of the 3-D printed models secondary to external forces. Third, limitation of current 3-D printing technologies lies in the production of a static model of a dynamic organ, which makes it difficult to comprehend the hemodynamic function of the cardiovascular system. Local and systematic flow dynamics of 3-D printed models were analyzed using 4-D MRI in two studies with findings comparable to *in vivo* flow pattern analysis and numerical simulations using computational fluid dynamics (7, 13). Future studies should be conducted to generate 3-D printed dynamic models capable of replicating both anatomic and physiological changes during the cardiac cycle, which could further improve understanding of the complex cardiovascular and cerebrovascular diseases. Finally, the cost associated with 3-D printing is still high. The cost is quite variable as it depends on the materials used for 3-D printing and the size and complexity of the model.

From a clinical perspective, future applications will aim to establish patient-specific 3-D printed models in routine clinical practice for individual patient treatments. Further potential applications of 3-D printing in cardiovascular and cerebrovascular diseases include the development of 3-D printed models that simulate characteristics of specific tissues, such as arteries and muscles, thus maximizing treatment outcomes and reducing complications. Bioprinting represents another major advance in 3-D printing involving the development of printable biomaterials, 3-D printed tissue scaffolds, and 3-D printed stem cells and functional vascular networks (5, 58–60). Applications of 3-D bioprinting have not translated into clinical practice. We refer the readers to some excellent reviews on 3-D or even 4-D bioprinting (58–62).

## Conclusion

This systematic review shows the feasibility and accuracy of using 3-D patient-specific printed models in the diagnostic assessment of cardiovascular and cerebrovascular diseases. 3-D printed models can also serve as a valuable tool for both education and pre-surgical planning and simulation. Future studies should focus on developing 3-D printed models with more realistic mechanical properties of replicating cardiovascular and cerebrovascular anatomy and hemodynamic features to optimize treatment for cardiovascular and cerebrovascular diseases.

**Conflict of interest:** None declared.

**Peer-review:** Externally peer-reviewed.

**Authorship contributions:** Concept – Z.S.; Design - Z.S.; Supervision- Z.S.; Data collection &/or processing – Z.S., S.L.; Analysis &/or interpretation – Z.S., S.L.; Literature search – Z.S., S.L.; Writing –Z.S.; Critical review – Z.S., S.L.

## References

1. Michalski MH, Ross JS. The shape of things to come: 3-D printing in medicine. *JAMA* 2014; 312: 2213-4. [CrossRef]
2. Rengier F, Mehndirata A, von Tengg-Kobligh H, Zechmann CM, Unterhinninghofen R, Kauczor HU, et al. 3-D printing based on imaging data: review of medical applications. *Int J Comput Assist Radiol Surg* 2010; 5: 335-41. [CrossRef]
3. Kim GB, Lee S, Kim H, Yang DH, Kim YH, Kyung YS, et al. Three-dimensional printing: basic principles and applications in medicine and radiology. *Korean J Radiol* 2016; 17: 182-97. [CrossRef]
4. Giannopoulos AA, Steigner ML, George E, Barile M, Hunsaker AR, Rybicki FJ, et al. Cardiothoracic applications of 3-dimensional printing. *J Thorac Imaging* 2016; 31: 253-72. [CrossRef]
5. Giannopoulos AA, Mitsouras D, Yoo SJ, Liu PP, Chatzizisis YS, Rybicki FJ. Applications of 3D printing in cardiovascular diseases. *Nat Rev Cardiol* 2016; 13: 701-18. [CrossRef]
6. Moher D, Shamseer L, Clarke M, Ghersi D, Liberati A, Petticrew M, et al. Preferred reporting items for systematic review and meta-analysis protocols (PRISMA-P) 2015 Statement. *Syst Rev* 2015; 4:1.
7. Anderson JR, Diaz O, Klucznik R, Zhang YJ, Britz GW, Grossman RG, et al. Validation of computational fluid dynamics methods with anatomically exact, 3-D printed MRI phantoms and 4D pcMRI. *Conf Proc IEEE Eng Med Biol Soc* 2014; 2014: 6699-701. [CrossRef]
8. Anwar S, Singh GK, Varughese J, Nguyen H, Billadello JJ, Sheybani EF, et al. 3-D printing in complex congenital heart disease: Across a spectrum of age, pathology, and imaging techniques. *JACC Cardiovasc Imaging* 2016 Jul 14. Epub ahead of print.
9. Bartel T, Rivard A, Jimenez A, Edris A. Three-dimensional printing for quality management in device closure of interatrial communications. *Eur Heart J Cardiovasc Imaging* 2016; 17: 1069. [CrossRef]
10. Biglino G, Capelli C, Wray J, Schievano S, Leaver LK, Khambadkone S, et al. 3D-manufactured patient-specific models of congenital heart defects for communication in clinical practice: feasibility and acceptability. *BMJ Open* 2015; 5: e007165. [CrossRef]
11. Biglino G, Capelli C, Koniordou D, Robertshaw D, Leaver LK, Schievano S, et al. Use of 3-D models of congenital heart disease as an education tool for cardiac nurses. *Congenit Heart Dis* 2017; 12: 113-8.
12. Binder TM, Moertl D, Mundigler G, Rehak G, Franke M, Delle-Karth G, et al. Stereolithographic biomodeling to create tangible hardcopies of cardiac structures from echocardiographic data: in vitro and in vivo validation. *J Am Coll Cardiol* 2000; 35: 230-7. [CrossRef]
13. Canstein C, Cachot P, Faust A, Stalder AF, Bock J, Frydrychowicz A, et al. 3D MR flow analysis in realistic rapid-prototyping model systems of the thoracic aorta: comparison with in vivo data and computational fluid dynamics in identical vessel geometries. *Magn Reson Med* 2008; 59: 535-46. [CrossRef]
14. Costello JP, Olivieri LJ, Su L, Krieger A, Alfares F, Thabit O, et al. Incorporating three-dimensional printing into a simulation-based congenital heart disease and critical care training curriculum for resident physicians. *Congenit Heart Dis* 2015; 10: 185-90. [CrossRef]
15. Dankowski R, Baszko A, Sutherland M, Firek L, Kalmucki P, Wroblewska K, et al. 3D heart model printing for preparation of percutaneous structural interventions: description of the technology and case report. *Kardiol Pol* 2014; 72: 546-51. [CrossRef]
16. D'Urso PS, Thompson RG, Atkinson RL, Weidmann MJ, Redmond MJ, Hal BI, et al. Cerebrovascular biomodelling: A technical note. *Surg Neurol* 1999; 52: 490-500. [CrossRef]
17. Farooqi K, Uppu SC, Nguyen K, Srivastava S, Ko HH, Choueier N, et al. Application of virtual three-dimensional models for simultaneous visualization of intracardiac anatomic relationships in double outlet right ventricle. *Pediatr Cardiol* 2016; 37: 90-8. [CrossRef]
18. Gallo M, D'Onofrio A, Tarantini G, Nocerino E, Remondino F, Gerosa G. 3-D-printing model for complex aortic transcatheter valve treatment. *Int J Cardiol* 2016; 210: 139-40. [CrossRef]
19. Gosnell J, Pietila T, Samuel BP, Kurup HK, Haw MP, Vettukattil JJ. Integration of computed tomography and three-dimensional echocardiography for hybrid three-dimensional printing in congenital heart disease. *J Digit Imaging* 2016; 29: 665-9. [CrossRef]
20. Greil GF, Wolf I, Kuettnner A, Fenchel M, Miller S, Martirosian P, et al. Stereolithographic reproduction of complex cardiac morphology based on high spatial resolution imaging. *Clin Res Cardiol* 2007; 96: 176-85. [CrossRef]
21. Itagaki MW. Using 3-D printed models for planning and guidance during endovascular intervention: a technical advance. *Diagn Interv Radiol* 2015; 21: 338-41. [CrossRef]
22. Jacobs S, Grunert R, Mohr FW, Falk V. 3D-imaging of cardiac structures using 3D heart models for planning in heart surgery: a preliminary study. *Interact Cardiovasc Thorac Surg* 2008; 7: 6-9. [CrossRef]
23. Kimura T, Morita A, Nishimura K, Aiyama H, Itoh H, Fukaya S, et al. Simulation of and training for cerebral aneurysm clipping with 3-dimensional models. *Neurosurgery* 2009; 65: 719-25. [CrossRef]
24. Lim KH, Loo ZY, Goldie SJ, Adams JW, McMenamin PG. Use of 3D printed models in medical education: A randomized controlled trial comparing 3D prints versus cadaveric materials for learning external cardiac anatomy. *Anat Sci Educ* 2016; 9: 213-21. [CrossRef]
25. Little SH, Vukicevic M, Avenatti E, Ramchandani M, Barker CM. 3D printed modelling for patient-specific mitral valve intervention: repair with a clip and a plug. *JACC Cardiovasc Interv* 2016; 9: 973-5.
26. Maragiannis D, Jackson MS, Igo SR, Schutt RC, Connell P, Grande-Allen J, et al. Replicating patient-specific severe aortic valve stenosis with functional 3D modelling. *Circ Cardiovasc Imaging* 2015; 8: e003626. [CrossRef]
27. Mashiko T, Otani K, Kawano R, Konno T, Kaneko N, Ito Y, et al. Development of three-dimensional hollow elastic model for cerebral aneurysm clipping simulation enabling rapid and low cost prototyping. *World Neurosurg* 2015; 83: 351-61. [CrossRef]
28. Mottl-Link S, Hubler M, Kuhne T, Rietdorf U, Krueger JJ, Schnackenburg B, et al. Physical models aiding in complex congenital heart surgery. *Ann Thorac Surg* 2008; 86: 273-7. [CrossRef]

29. Namba K, Higaki A, Kaneko N, Mashiko T, Nemoto S, Watanabe E. Microcatheter shaping for intracranial aneurysm coiling using the 3-dimensional printing rapid prototyping technology: preliminary result in the first 10 consecutive cases. *World Neurosurg* 2015; 84: 178-86. [\[CrossRef\]](#)
30. Ngan EM, Rebeyka IM, Ross DB, Hirji M, Wolfaardt JF, Seelaus R, et al. The rapid prototyping of anatomic models in pulmonary atresia. *J Thorac Cardiovasc Surg* 2006; 132: 264-9. [\[CrossRef\]](#)
31. Noecker AM, Chen JF, Zhou Q, White RD, Kopcak MW, Arruda MJ, et al. Development of patient-specific three-dimensional pediatric cardiac models. *ASAIO J* 2006; 52: 349-53. [\[CrossRef\]](#)
32. Olivieri LJ, Krieger A, Loke YH, Nath DS, Kim PC, Sable CA, et al. Three-dimensional printing of intracardiac defects from three-dimensional echocardiographic images: feasibility and relative accuracy. *J Am Soc Echocardiogr* 2015; 28: 392-7. [\[CrossRef\]](#)
33. Olivieri LJ, Krieger A, Chen MY, Kim P, Kanter JP. 3D heart model guides complex stent angioplasty of pulmonary venous baffle obstruction in a Mustard repair of D-TGA. *Int J Cardiol* 2014; 172: e297-e8. [\[CrossRef\]](#)
34. O'Neill B, Wang DD, Pantelic M, Song T, Guerrero M, Greenbaum A, et al. Transcatheter caval valve implantation using multimodality imaging: Role of TEE, CT and 3D printing. *JACC Cardiovasc Imaging* 2015; 8: 221-5. [\[CrossRef\]](#)
35. Otton JM, Spina R, Sulas R, Subbiah RN, Jacobs N, Muller DWM, et al. Left atrial appendage closure guided by personalized 3D-printed cardiac reconstruction. *JACC Cardiovasc Interv* 2015; 8: 1004-6. [\[CrossRef\]](#)
36. Poterucha JT, Foley TA, Taggart NW. Percutaneous pulmonary valve implantation in a native outflow tract: 3-dimensional dynaCT rotational angiographic reconstruction and 3-dimensional printed model. *JACC Cardiovasc Interv* 2014; 7: e151-2. [\[CrossRef\]](#)
37. Ripley B, Kelil T, Cheezum MK, Goncalves A, Di Carli MF, Rybicki FJ, et al. 3D printing based on cardiac CT assists anatomic visualization prior to transcatheter aortic valve replacement. *J Cardiovasc Comput Tomogr* 2016; 10: 28-36. [\[CrossRef\]](#)
38. Ryan JR, Moe TG, Richardson R, Frakes DH, Nigro JJ, Pophal S. A novel approach to neonatal management of tetralogy of Fallot, with pulmonary atresia, and multiple aortopulmonary collaterals. *JACC Cardiovasc Imaging* 2015; 8: 103-4. [\[CrossRef\]](#)
39. Salloum C, Lim C, Fuentes L, Osseis M, Luciani A, Azoulay D. Fusion of information from 3D printing and surgical robot: An innovative minimally technique illustrated by the resection of a large celiac trunk aneurysm. *World J Surg* 2016; 40: 245-7. [\[CrossRef\]](#)
40. Samuel BP, Pinto C, Pietila T, Vettukattil JJ. Ultrasound-derived three-dimensional printing in congenital heart disease. *J Digit Imaging* 2015; 28: 459-61. [\[CrossRef\]](#)
41. Schievano S, Migliavacca F, Coats L, Khambadkone S, Carminati M, Wilson N, et al. Percutaneous pulmonary valve implantation based on rapid prototyping of right ventricular outflow tract and pulmonary trunk from MR data. *Radiology* 2007; 242: 490-7. [\[CrossRef\]](#)
42. Schievano S, Taylor AM, Capelli C, Coats L, Walker F, Lurz P, et al. First-in-human implantation of a novel percutaneous valve: a new approach to medical device development. *EuroIntervention* 2010; 5: 745-50. [\[CrossRef\]](#)
43. Schmauss D, Haeberle S, Hagl C, Sodian R. Three-dimensional printing in cardiac surgery and interventional cardiology: a single-centre experience. *Eur J Cardiothorac Surg* 2015; 47: 1044-52. [\[CrossRef\]](#)
44. Shiraishi I, Yamagishi M, Hamaoka K, Fukuzawa M, Yagihara T. Simulative operation on congenital heart disease using rubber-like urethane stereolithographic biomodels based on 3D datasets of multislice computed tomography. *Eur J Cardiothorac Surg* 2010; 37: 302-6.
45. Sodian R, Weber S, Market M, Rassoulain D, Kaczmarek I, Lueth TC, et al. Stereolithographic models for surgical planning in congenital heart surgery. *Ann Thorac Surg* 2007; 83: 1854-7. [\[CrossRef\]](#)
46. Sodian R, Weber S, Markert M, Loeff M, Lueth T, Weis FC, et al. Pediatric cardiac transplantation: three-dimensional printing of anatomic models for surgical planning of heart transplantation in patients with univentricular heart. *J Thorac Cardiovasc Surg* 2008; 136: 1098-9. [\[CrossRef\]](#)
47. Sodian R, Schmauss D, Markert M, Weber S, Nikolaou K, Haeberle S, et al. Three-dimensional printing creates models for surgical planning of aortic valve replacement after previous coronary bypass grafting. *Ann Thorac Surg* 2008; 85: 2105-9. [\[CrossRef\]](#)
48. Sodian R, Schmauss D, Schmitz C, Bigdeli A, Haeberle S, Schmoeckel M, et al. 3-dimensional printing of models to create custom-made devices for coil embolization of an anastomotic leak after aortic arch replacement. *Ann Thorac Surg* 2009; 88: 974-8. [\[CrossRef\]](#)
49. Sun Z, Squelch A. Patient-specific 3D printed models of aortic aneurysm and aortic dissection. *J Med Imaging Health Inf* 2016 Jul 15.
50. Tam MD, Laycock SD, Brown JR, Jakeways M. 3D printing of an aortic aneurysm to facilitate decision making and device selection for endovascular aneurysm repair in complex neck anatomy. *J Endovasc Ther* 2013; 20: 863-7. [\[CrossRef\]](#)
51. Valverde I, Gomez G, Gonzalez A, Suarez-Mejias C, Adsuar A, Cosseria JF, et al. Three-dimensional patient-specific cardiac model for surgical planning in Nikaidoh procedure. *Cardiol Young* 2015; 25: 698-704. [\[CrossRef\]](#)
52. Valverde I, Gomez G, Cosseria JF, Suarez-Mejias C, Uribe S, Sotelo J, et al. 3D printed models for planning endovascular stenting in transverse aortic arch hypoplasia. *Catheter Cardiovasc Interv* 2015; 85: 1006-12. [\[CrossRef\]](#)
53. Vranicar M, Gregoroy W, Douglas WI, Di Sessa P, Di Sessa TG. The use of stereolithographic hand held models for evaluation of congenital anomalies of the great vessels. *Stud Health Technol Inform* 2008; 132: 538-43.
54. Wurm G, Lehner M, Tomancok B, Kleiser R, Nussbaumer K. Cerebrovascular biomodeling for aneurysm surgery: simulation-based training by means of rapid prototyping technologies. *Surg Innov* 2011; 18: 294-306. [\[CrossRef\]](#)
55. Farooqi KM, Nielsen JC, Uppu SC, Srivastava S, Parness IA, Sanz J, et al. Use of a 3-dimensional printing to demonstrate complex intracardiac relationships in double-outlet right ventricle for surgical planning. *Circ Cardiovasc Imaging* 2015; 8: e003043. [\[CrossRef\]](#)
56. Schmauss D, Gerber N, Sodian R. Three-dimensional printing of models for surgical planning in patients with primary cardiac tumors. *J Thorac Cardiovasc Surg* 2013; 145: 1407-8. [\[CrossRef\]](#)
57. Schmauss D, Schmitz C, Bigdeli AK, Weber S, Gerber N, Beiras-Fernandez A, et al. Three-dimensional printing of models for preoperative planning and simulation of transcatheter valve placement. *Ann Thorac Surg* 2012; 93: e31-3. [\[CrossRef\]](#)
58. Jan J, Park HJ, Kim SW, Kim H, Park JY, Na SJ, et al. 3D printing complex tissue construct using stem cell-laden decellularized extracellular matrix bioinks for cardiac repair. *Biomaterials* 2017; 112: 264-74.
59. Özbolat IT, Hospodiuk M. Current advances and future perspectives in extrusion-based bioprinting. *Biomaterials* 2016; 76: 321-43.
60. Tricomi BJ, Dias AD, Corr DT. Stem cell bioprinting for applications in regenerative medicine. *Ann N Y Acad Sci* 2016; 1383: 115-24.
61. Li YC, Zhang YS, Akpek A, Shin SR, Khademhosseini A. 4D bioprinting: the next-generation technology for biofabrication enabled by stimuli-responsive materials. *Biofabrication* 2016; 9: 012001.
62. Murphy SV, Atala A. 3D bioprinting of tissues and organs. *Nat Biotechnol* 2014; 32: 773-85. [\[CrossRef\]](#)