

Cardiac catheterization procedures in pediatric patients undergoing extracorporeal membrane oxygenation cardiac catheterization, ECMO

Alper Güzeltaş, Taner Kasar, İbrahim Cansaran Tanıdır, Erkut Öztürk, Okan Yıldız*, Sertaç Haydin*

Departments of Pediatric Cardiology and *Pediatric Cardiovascular Surgery, İstanbul Sağlık Bilimleri University, İstanbul Mehmet Akif Ersoy Thoracic and Cardiovascular Surgery Education and Research Hospital, İstanbul-Turkey

ABSTRACT

Objective: Extracorporeal membrane oxygenation (ECMO) is a lifesaving intervention for pediatric patients with respiratory and/or cardiovascular failure. In this study, we evaluated the cardiac catheterization results of pediatric patients on ECMO support.

Methods: Between January 2012 and October 2016, 98 patients (5.2% of all surgery patients) needed ECMO support during perioperative cardiac surgery. We retrospectively reviewed the clinical data of 16 patients who underwent cardiac catheterization under ECMO support.

Results: The median age at catheterization was 6.5 months (range, 3.3–60 months), and the median weight was 6.0 kg (range, 3.7–16 kg). Eight of the catheterizations were diagnostic, and the remaining eight were interventional. Five out of these eight patients underwent surgical palliation after diagnostic catheterization. Right pulmonary artery (RPA) stenting, right ventricular outflow tract (RVOT) stenting, combined left pulmonary artery (LPA) and RVOT stenting, combined LPA and modified Blalock-Taussig shunt stenting, bilateral pulmonary artery balloon angioplasty, and bilateral pulmonary artery stenting were each performed once, whereas LPA stenting was performed in two different patients. In one patient undergoing RVOT stenting, a complete atrioventricular block developed, resulting in hypotension; however, this was overcome with an ECMO flow increase. In another patient, the ECMO tubing disconnected from the arterial line. Minor vascular complications were seen in three patients. Twelve patients (75%) were successfully weaned from ECMO after the procedure and ten (63%) were discharged.

Conclusion: Diagnostic and interventional cardiac catheterization can be safely and effectively performed in patients on ECMO. If the patient cannot be weaned from ECMO support, clinicians should consider performing an early angiogram either to treat or clarify the underlying problem.

Keywords: cardiac catheterization, child, infant, extracorporeal membrane oxygenation, ECMO (*Anatol J Cardiol* 2017; 18: 425-30)

Introduction

In recent years, extracorporeal membrane oxygenation (ECMO) support has become a standard treatment modality in the management of respiratory and cardiac failure in both pediatric and adult patients (1). ECMO can be useful for the preoperative hemodynamic stabilization of patients with congenital heart disease (CHD), fatal arrhythmias resistant to medical treatment, unexplained sudden cardiac arrest, low cardiac output syndrome after cardiac surgery, or as a bridge to other treatment modalities (1-2).

In some patients, an investigation of the underlying etiology creating a need for ECMO cannot be revealed by noninvasive methods, such as magnetic resonance imaging, computed tomography, and echocardiography. In these cases, cardiac catheterization and angiography could be an alternative method. Cardiac catheterization has the advantages of both diagnosing the reason

for ECMO requirement and providing an opportunity for the correction of a residual defect (3-4).

In this study, we evaluated cardiac catheterization results in pediatric heart patients on ECMO support.

Methods

All pediatric patients on ECMO undergoing cardiac catheterization between January 2012 and October 2016 were included in this study. The medical records for all of these patients were retrospectively reviewed, collecting the following information: age; weight; diagnosis; primary surgical procedure; indication for ECMO; ECMO duration; indication for catheterization; timing of catheterization; and details of catheterization, including the procedure, complications, and clinical outcomes.

The ECMO circuit comprised a Deltastream® DP3 diagonal pump head (Medos Medizintechnik AG, Stolberg, Germany), a Hi-

Address for correspondence: Dr. Alper Güzeltaş, İstanbul Sağlık Bilimleri Üniversitesi Mehmet Akif Ersoy Eğitim Araştırma Hastanesi, İstasyon Mahallesi, İstanbul Caddesi, Bezirganbağçe Mevki 34303 Küçükçekmece, İstanbul-Türkiye
Phone: +90 212 692 20 00 Fax: +90 212 471 94 94 E-mail: alperguzeltas@hotmail.com

Accepted Date: 29.09.2017 **Available Online Date:** 07.12.2017

©Copyright 2017 by Turkish Society of Cardiology - Available online at www.anatoljcardiol.com
DOI:10.14744/AnatolJCardiol.2017.7927



Table 1. Demographic datas

Age, months	6.5	3.3–60
Weight, kg	6.0	3.7–16
Gender	10 male/8 female	
Ventricular morphology		
Biventricular	13	81%
PA with VSD	5	
Tetralogy of Fallot	3	
TGA-VSD-PS	2	
SVAS	1	
DORV-VSD-PS	1	
Truncus arteriosus	1	
Univentricular	3	19%
HLHS	2	
Unbalanced cAVSD	1	
The duration of transport, min	7 min.	6-15 min.
Procedural datas		
Diagnostic	8	50%
Interventional	8	50%
Duration of procedure	45 min	15–210 min
Duration of fluoroscopy	14 min	2.5-97 min
Days prior to catheterization	3 days	1-11 days
Days to decannulate following catheterization	3 days	0-6 days
<small>cAVSD-complete atrioventricular septal defect, DORV-double outlet right ventricle, PA-pulmonary atresia, PS-pulmonary stenosis, SVAS-supravalvular aortic stenosis, TGA-transposition of giant arteries, VSD-ventricular septal defect</small>		

lite® (Medos Medizintechnik AG, Stolberg, Germany) polymethylpentene (PMP) diffusion membrane oxygenator, and a Rheoparin (Medos Medizintechnik AG, Stolberg, Germany) coated tubing for both arterial and venous lines. The system was complemented with a MDC console, which also included valuable safety mechanisms, such as a flow sensor with an integrated bubble detector, backflow detection, and temperature sensors.

Venoarterial ECMO was performed in all patients. Ascending aorta and right atrium cannulations were preferred for extracorporeal life support during the postoperative first 15 days. In addition, DLP cannulas (Medtronic, Inc., Minneapolis, MN) were preferred for cardiopulmonary bypass (CPB) procedures in these patients. Neck cannulation and Biomedicus (Medtronic, Inc., Minneapolis, MN) cannulas were preferred in the preoperative patients and after the postoperative 15th day.

An additional 50–100 IU/kg of heparin was introduced according to the initial activated clotting time (ACT). A continuous heparin infusion was initiated at a dosage to maintain ACT between 180 and 200 s or the activated partial thromboplastin time between 60 and 80 s, and the dosage was titrated. Heparin was excluded from all of the intravenous treatments, with

fondaparinux being initiated once daily at a dosage of 0.1 mg/kg in patients in whom heparin-induced thrombocytopenia developed. The antifactor Xa levels were titrated at 0.3–0.6 IU/mL.

The ECMO pump flow was initiated at 150 mL/kg/min and was changed after maintenance of the end-organ perfusion, an increase in the systemic venous sO_2 , and a decrease in lactic acidosis. High flow rates (e.g., 200 mL/kg/min) were preferred in patients with single ventricles and open shunts. The use of pulsatility was dependent on the heart beats. If there were no heart beats, pulsatile flow was used. ECMO was started on the speed control mode to provide hemodynamic stability. The P1 control mode (the pressure between the venous cannula and the pump head) was then set if the patient had no bleeding.

Angiograms were performed in the Philips Allura Xper FD10-10 biplane catheterization laboratory. Because of the antegrade ECMO flow, the cineangiography image quality might be poor, particularly during contrast injections. If the patient's systemic perfusion was not fully ECMO dependent, the ECMO flow was temporarily discontinued; however, if the patient's cardiac output was fully ECMO dependent, the ECMO flow was reduced. In some patients, the ECMO flow might have been diminished or temporarily discontinued to document the "real" cardiac hemodynamics.

The transport safety of the DP3 system was satisfactory. When the patients were hemodynamically stable, with a minimal ECMO flow (<25% of full flow), and the recovery of adequate myocardial contractility was evidenced by echocardiography, the patients were weaned off ECMO.

Statistical analysis

The distribution of the variables in this study was classified via computerized media, and the statistical data were gathered using the Statistical Package for the Social Sciences (SPSS) for Windows version 15 (SPSS Inc., Chicago, USA). The demographic variables were presented as the mean±standard deviation, median (range), and the absolute and percentage frequency values as continuous variables.

Results

Patients

Between January 2012 and October 2016, 98 patients (5.2% of the surgery patients) needed venoarterial ECMO support during perioperative cardiac surgery. Either diagnostic or interventional cardiac catheterization was performed in 16 (16.3%) of these 98 patients. Ten patients were males and the remaining six were females. Their median age was 6.5 months (range, 3.3–60 months), and their median weight was 6.0 kg (range, 3.7–16 kg). The demographic data of the patients are summarized in Table 1.

Indications and use of ECMO

The indications for ECMO were hemodynamic instability in 10 patients, hypoxemia in three, inability to terminate the intraopera-

Table 2. Interventional procedures and outcome

Procedure	Postprocedural ECMO weaning	Discharge
Stenting LPA and mBT shunt	Yes	Yes
Balloon dilatation and stenting of left pulmonary artery	No	–
Balloon dilatation of RPA and LPA*	Yes	Yes
Stenting of left pulmonary artery	No	–
Stenting both RVOT and LPA+Balloon dilatation of the central shunt	Yes	No
RVOT Stenting	Yes	Yes
Balloon dilatation of LPA	No	–
Stenting both RPA and LPA	Yes	Yes

* This patient underwent surgery five days after interventional catheterization.
 LPA-left pulmonary artery, mBT-modified Blalock-Taussig shunt, RPA-right pulmonary artery, RVOT-right ventricular outflow tract

tive bypass in two, and cardiac arrest during catheterization in one. Venoarterial ECMO was used in all 16 patients. In 12 of the 16 patients requiring support in the immediate (1–24 h) postoperative period, direct cannulation (via the original sternotomy) of the aorta and right atrium was employed. Of the 16 patients, four had right cervical cannulation throughout their ECMO course. The median ECMO period was 7 days (range, 2–15 days).

Cardiac catheterization procedures

All patients were transferred from the intensive care unit (ICU) to the catheter laboratory, with a median transfer time of 7 min (range, 6–15 min) (Table 1). In 14 patients, the femoral artery or vein was used for vascular access. In the remaining two patients, the right subclavian vein and the right jugular vein were used, respectively. In six patients, ultrasound guidance was used for the percutaneous access, and in the remaining ten patients, previously placed access sites were used. Before cardiac catheterization, all patients had undergone transthoracic and/or

transesophageal echocardiographic evaluations while on ECMO, which were either inconclusive for the etiology of the clinical condition or suggestive of the presence of complex residual lesions requiring diagnostic and/or therapeutic catheterization (Fig. 1-2).

The median duration from the initiation of ECMO support to the catheterization procedure was 3 days (range, 1–11 days). Diagnostic catheterizations were performed in eight patients, whereas interventional procedures were performed in the remaining eight. The following procedures were performed: left pulmonary artery (LPA) stenting (n=1), right pulmonary artery (RPA) stenting (n=1), bilateral pulmonary artery stenting (n=1), right ventricular outflow tract (RVOT) stenting (n=1), combined LPA and RVOT stenting (n=1), combined LPA and modified Blalock Taussig (mBT) shunt stenting (n=1), bilateral pulmonary artery balloon angioplasty (n=1), and LPA balloon angioplasty (n=1) (Table 2).

In one patient, during the RVOT stenting, a complete atrioventricular (AV) block developed, resulting in hypotension. This problem was overcome with an ECMO flow increase. No com-

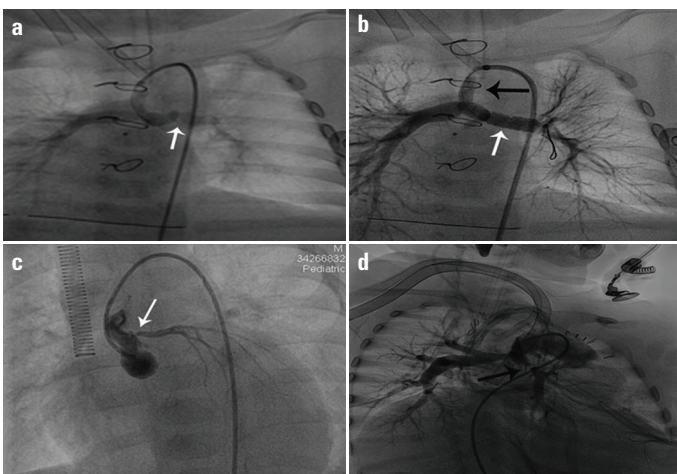


Figure 1. (a) First patient, left mBT shunt flow is decreased and severe stenosis on left pulmonary artery is seen (white arrow), (b) First patient, left mBT shunt (black arrow) and left pulmonary artery (white arrow) stents, (c) stenosis on the left main coronary artery (white arrow); patient underwent surgery, (d) stenosis in the middle of the left pulmonary artery (black arrow)

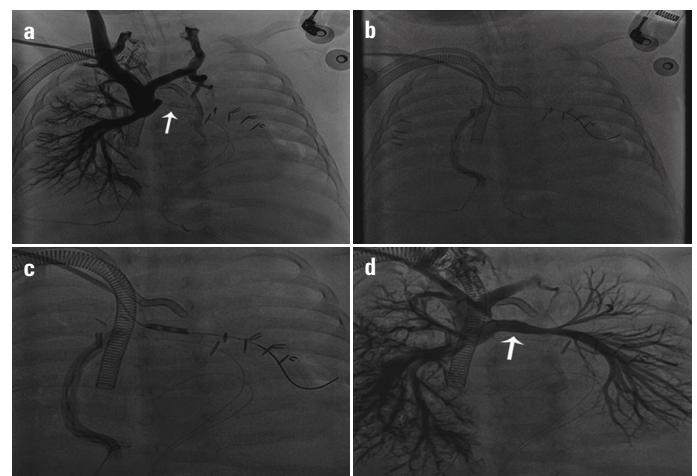


Figure 2. (a) Fourth patient: angiogram reveals no antegrade flow into the left pulmonary artery (white arrow), (b) and (c) balloon angioplasty and stenting for the stenosis on the left pulmonary artery, (d) final angiogram reveals increased antegrade flow after the procedure

Table 3. Characteristics of patients weaned from ECMO

	Successful n (%)	Unsuccessful n (%)	Total n (%)
Weaning from ECMO support	12 (75)	4 (25)	16 (100)
ECMO indication			
Hemodynamic instability	8 (72)	3 (28)	11 (69)
Hypoxemia	2 (100)	–	2 (12)
Inability for termination of intraoperative bypass	2 (100)	–	2 (12)
Cardiac arrest during catheterization	–	1 (100)	1 (6)
CPR need	6 (75)	2 (25)	8 (50)
Catheterization type			
Diagnostic catheterization	7 (87)	1 (13)	8 (50)
Interventional catheterization	5 (63)	3 (37)	8 (50)
Surgery after catheterization	5 (100)	–	5 (30)
Outcome			
Survivor	10 (100)	–	10 (62)
NonSurvivor	2 (33)	4 (66)	6 (38)

plications occurred during the transfer period; however, after the cardiac catheterization in one patient, the ECMO tubing disconnected from the arterial line while transferring the patient from the angiography table to the patient’s bed. There were no system-related complications or adverse effects recorded during transport.

Three patients had minor complications related to the catheterization procedure. Of these, two patients had coagulopathies and required prolonged compression of the femoral puncture site, and one patient had oozing from the venous catheter site and was managed by exchanging the original catheter for a larger one. No complications related to ECMO cannulas or endotracheal tubes during transport (and within 1 h of return to ICU) were encountered.

Overall outcomes and survival

Overall 12 patients (75%) were successfully weaned from ECMO after the procedure, whereas four patients died under

ECMO support during their ICU stay (Table 3, Fig. 3). In patients in whom ECMO support was terminated due to death, the diagnoses included severe neurological damage (n=2), septicemia (n=1), and multiorgan failure (n=1). In three of the four patients, interventional procedures were performed, whereas the remaining patient underwent diagnostic cardiac catheterization.

Four patients were operated on following the diagnostic catheterization and one was operated on after interventional catheterization. In three patients, conduit replacements were performed. Of these three patients, right and left pulmonary artery stenoses were corrected in one patient and supravalvular obstruction and coronary ostium stenosis corrections were performed in one. All of these patients were successfully weaned from ECMO support.

Two of the 12 patients weaned from ECMO support died during the ICU follow-up. The causes of death were multiple organ failure in one and severe neurological damage in the other. Both of them had diagnostic cardiac catheterizations (Table 3).

Ten patients were discharged, with a median follow-up time of 22 months (range, 6–46 months). Two of the 10 discharged patients had neurological damage (loss of vision in one and mental retardation in the other). One patient had an mBT shunt revision after 6 months, and one patient had a conduit replacement after 2 years.

Discussion

In this study, we evaluated the indications, interventional applications, and survival outcomes of catheterization procedures in patients on ECMO support. This study was conducted in a tertiary heart surgery center wherein ECMO support is widely used. By evaluating the results of 16 patients, we attempted to highlight the basics for catheterization of patients on ECMO, regarding

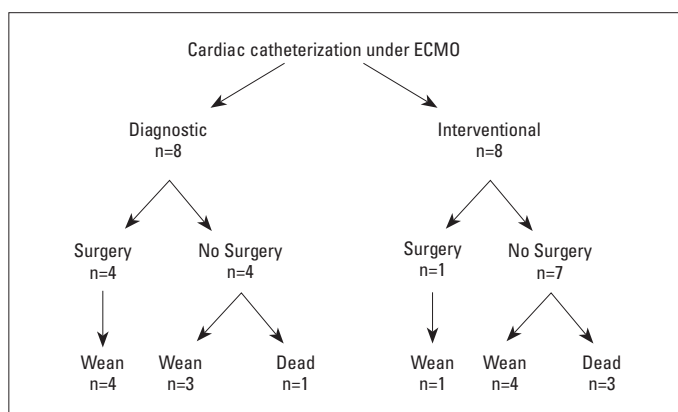


Figure 3. Characteristics of patients weaned from ECMO

which there are a limited number of studies.

Today, ECMO is used in several conditions for treating cardiac surgery patients, such as those with recurrent cardiac arrests requiring continuous resuscitation, low cardiac output despite sufficient inotropic support, myocarditis, uncontrollable ventricular tachycardia and ventricular fibrillation episodes, and support requirements before and after transplantation (5).

In the literature, the cardiac ECMO utilization rate has been reported as 7.9–12.7 patients/year in different studies. The rate of cardiac catheterization in patients on ECMO is 3.5–7.1 patients/year, which equals to the catheterization rate under ECMO, which is about 30% (3, 6-7). In our study, these rates were 19.6 patients/year and 3.2 patients/year, while the rate of catheterization on ECMO was 16.8%. Booth et al. (3) reported their catheterization rate for patients on ECMO as 28% (54/192 patients). Among these patients, 38 had CHD (24 double ventricle vs. 14 single ventricle), and the remaining 16 had cardiomyopathies. The indications for ECMO included low cardiac output in 31 patients (55%), sudden cardiac arrest in 13 (23%), hypoxemia in six (11%), failure to wean from CPB in four (7%), and refractory arrhythmias in two (4%). In addition, Panda et al. (8) reported a series including 22 cardiac catheterizations out of 59 patients on ECMO from February 2009 to August 2012. Seventeen of their patients had CHD and four had myocarditis. The procedure was performed in the operating room in nine patients and in ICU in 13. In seven patients, catheterization was performed under extracorporeal cardiopulmonary resuscitation (E-CPR) (8).

All patients in our study had CHD, with the most common diagnoses being ventricular septal defect (VSD) with pulmonary atresia (n=4), tetralogy of Fallot (n=2), and transposition of the great arteries with a VSD and pulmonary stenosis (n=2). Fourteen patients (88%) had double ventricle physiologies. Profound hemodynamic instability was present in 10 patients (63%), and ECMO support was instituted under E-CPR in eight patients (50%).

The indications for cardiac catheterization in patients on ECMO support have been reported in several different studies (4, 6, 8). For example, Panda et al. (8) reported 15 postoperative patients undergoing 21 cardiac catheterizations for the assessment of possible undiagnosed or residual lesions, hemodynamic studies, or planned catheter-based interventions. They evaluated coronary anomalies in primary cardiomyopathies in four cases, whereas other two cases were evaluated for resistant arrhythmia.

Callahan et al. (9) reported 40 cardiac catheterizations in 36 patients. The indications for catheterization included an assessment of postoperative hemodynamic/anatomical parameters (n=16), nonoperative patients (n=7), planned catheter interventions (n=12), and cardiomyopathy assessments (n=5). Unexpected diagnostic information was found in 21 patients (52%), and catheter interventions were aborted during 18 catheterizations (45%), including vessel/surgical shunts stents (n=9), balloon atrial septostomies (n=4), device closure of the septal wall/vessels (n=3), thrombolysis of the vessels (n=2), endomyocardial biopsies

(n=2), and a temporary pacemaker wire placement (n=1). Our catheter indications were unexplained hemodynamic instability in seven patients (43%) and interventional procedures in nine (57%). The interventions included either ballooning or stenting of pulmonary arteries.

Critically ill patients undergoing intrahospital transfer are generally at an increased risk for mortality and morbidity (10, 11). For patients on ECMO, one might expect that the risks of intrahospital transfer would be even higher. Fortunately, we did not see any complications during patient transport. However, after the cardiac catheterization in one patient, the ECMO cannula disconnected from the arterial line while transferring the patient from the angiography table to the patient's bed. Fortunately, the surgeon was near ECMO and was able to reconnect the tube to the circuit.

In the literature, variable access sites, such as the femoral artery, umbilical artery, internal jugular vein, and open chest, have been used for ECMO catheterization. The most preferred access site was the femoral route. In 20%–30% of the cases, the existing venous access was exchanged during catheterization and access was provided for the procedure (8-9, 12). In our study, femoral access was preferred in 88% of the cases, and in 10 patients, the access was provided by exchanging the existing venous catheter.

Different complications can be observed during a cardiac catheterization procedure. In a multicenter study reported by Bergersen et al. (13), the complication rate during congenital cardiac catheterization was 16% (range, 5%–18%). In addition, Callahan et al. (9) reported a complication rate of 15% in patients catheterized while on ECMO and proposed that ECMO did not increase the complication rate. In our study, there were more complications (five complications in three patients) than in Callahan's study, which might have been related to the presence of more interventional catheters in our series.

Surveillance after catheterization on ECMO depends on the clinical experience of the units, timing, and indications for ECMO and varies with the impact of technological advancement on the ECMO equipment. In the long run, it was noteworthy that survival increased in these cases (4, 14, 15). Booth et al. (3) reported that the weaning rate of ECMO as 72%, and discharge from the hospital as 48%. In their study, Callahan et al. (9) reported an 86% rate of successful decannulation, 72% rate of survival to discharge, and 88% rate of survival among the patients who underwent catheter interventions. Abraham et al. (6) reported that the survival rate was 83% and the transplant-free survival rate was 58.3% among the patients catheterized while on ECMO. Patients with CHD constituted 81.2% of their cohort. Recently, Burke et al. (4) reported the largest series and showed that patients who underwent early catheterization (≤ 72 h of ECLS initiation) required shorter total duration of ECLS than patients who underwent catheterization >72 h after ECLS initiation. Also, the survival to hospital discharge rate was higher in the early catheterization group (74% vs. 51%, $p=0.04$).

In our study, the rate of successful decannulation from ECMO was 75%, and the hospital discharge was 62% (10 patients) in patients who underwent cardiac catheterization. In addition, 63% of the patients in whom an intervention was performed and 100% of the patients requiring surgery after catheterization were successfully weaned from ECMO.

Study limitations

This was a retrospective, single-center study with a small sample size. All patients in our cohort had CHD, and there were no heart transplant, cardiomyopathy, or resistant arrhythmia patients, preventing the comparison of our results with other groups of patients. Another limitation was the small chance of long-term support options after ECMO in our country, such as ventricular assistance devices and heart transplantation.

Conclusion

Diagnostic and interventional cardiac catheterizations can be safely and effectively performed in patients on ECMO. If the patient cannot be weaned from ECMO support due to hemodynamic instability, clinicians should consider performing an angiogram either to treat or clarify the underlying problem. Transferring a patient from a bed to the angiography table may be the riskiest part of the transport; therefore, the ECMO team should exercise care during this process.

Funding: None declared.

Disclosure statement: The authors confirm that there are no conflicts of interest.

Conflict of interest: None declared.

Peer-review: Externally peer-reviewed.

Authorship contributions: Concept – A.G., T.K., İ.C.T., S.H.; Design – A.G., E.O., O.Y., S.H.; Supervision – A.G., S.H.; Data collection &/or processing – T.K., İ.C.T., E.O., O.Y.; Analysis &/or interpretation – T.K., İ.C.T., E.O.; Literature search – O.Y., E.O.; Writing – E.O., T.K., O.Y.; Critical review – A.G., S.H., İ.C.T.

References

- Öztürk E, Yıldız O, Cine N, Tüzün B, Onan S, Ergül Y, et al. The use of neonatal extracorporeal life support in pediatric cardiac intensive care unit. *J Matern Fetal Neonatal Med* 2017; 30: 1397-401. [\[CrossRef\]](#)
- Extracorporeal Life Support Organization. Extracorporeal Life Support Registry Report International Summary. Ann Arbor ME, 2013.
- Booth KL, Roth SJ, Perry SB, del Nido PJ, Wessel DL, Laussen PC. Cardiac catheterization of patients supported by extracorporeal membrane oxygenation. *J Am Coll Cardiol* 2002; 40: 1681-6. [\[CrossRef\]](#)
- Burke CR, Chan T, Rubio AE, McMullan DM. Early Cardiac Catheterization leads to shortened pediatric extracorporeal membrane oxygenation run duration. *J Interv Cardiol* 2017; 30: 170-6. [\[CrossRef\]](#)
- Alsoufi B, Awan A, Manlhiot C, Guechef A, Al-Halees Z, Al-Ahmadi M, et al. Results of rapid-response extracorporeal cardiopulmonary resuscitation in children with refractory cardiac arrest following cardiac surgery. *Eur J Cardiothorac Surg* 2014; 45: 268-75. [\[CrossRef\]](#)
- Abraham BP, Gilliam E, Kim DW, Wolf MJ, Vincent RN, Petit CJ. Early catheterization after initiation of extracorporeal membrane oxygenation support in children is associated with improved survival. *Catheter Cardiovasc Interv* 2016; 88: 592-9. [\[CrossRef\]](#)
- Agarwal HS, Hardison DC, Saville BR, Donahue BS, Lamb FS, Bichell DP, et al. Residual lesions in postoperative pediatric cardiac surgery patients receiving extracorporeal membrane oxygenation support. *J Thorac Cardiovasc Surg* 2014; 147: 434-41. [\[CrossRef\]](#)
- Panda BR, Alphonso N, Govindasamy M, Anderson B, Stocker C, Karl TR. Cardiac catheter procedures during extracorporeal life support: a risk-benefit analysis. *World J Pediatr Congenit Heart Surg* 2014; 5: 31-7. [\[CrossRef\]](#)
- Callahan R, Trucco SM, Wearden PD, Beerman LB, Arora G, Kreutzer J. Outcomes of pediatric patients undergoing cardiac catheterization while on extracorporeal membrane oxygenation. *Pediatr Cardiol* 2015; 36: 625-32. [\[CrossRef\]](#)
- Warren J, Fromm RE Jr, Orr RA, Rotello LC, Horst HM. Guidelines for the inter- and intrahospital transport of critically ill patients. *Crit Care Med* 2004; 32: 256-62. [\[CrossRef\]](#)
- Proadhan P, Fiser RT, Cenac S, Bhutta AT, Fontenot E, Moss M, et al. Intrahospital transport of children on extracorporeal membrane oxygenation: indications, process, interventions, and effectiveness. *Pediatr Crit Care Med* 2010; 11: 227-33. [\[CrossRef\]](#)
- Ward CJ, Mullins CE, Barron LJ, Grifka RG, Gomez MR, Cuellar-Gomez MR. Use of extracorporeal membrane oxygenation to maintain oxygenation during pediatric interventional cardiac catheterization. *Am Heart J* 1995; 130: 619-20. [\[CrossRef\]](#)
- Bergersen L, Marshall A, Gauvreau K, Beekman R, Hirsch R, Foerster S, et al. Adverse event rates in congenital cardiac catheterization - a multi-center experience. *Catheter Cardiovasc Interv* 2010; 75: 389-400.
- Kato A, Lo Rito M, Lee KJ, Haller C, Guerguerian AM, Sivarajan VB, et al. Impacts of early cardiac catheterization for children with congenital heart disease supported by extracorporeal membrane oxygenation. *Catheter Cardiovasc Interv* 2017; 89: 898-905. [\[CrossRef\]](#)
- Boscamp NS, Turner ME, Crystal M, Anderson B, Vincent JA, Torres AJ. Cardiac Catheterization in Pediatric Patients Supported by Extracorporeal Membrane Oxygenation: A 15-Year Experience. *Pediatr Cardiol* 2017; 38: 332-7. [\[CrossRef\]](#)