

Surgical experiences in acute spontaneous dissection of the infrarenal abdominal aorta

Akut spontan infrarenal abdominal aort disseksiyonlarında cerrahi deneyimlerimiz

Yusuf Kalko, Ülkü Kafa, Murat Başaran,
Taylan Köşker, Özerdem Özçalışkan, Erdal Yücel, Ünal Aydın, Tahsin Yaşar
Cardiovascular Surgery Service, Bezm-i Alem Vakif Gureba Hospital, İstanbul, Turkey

ABSTRACT

Objective: Spontaneous dissection of the abdominal aorta should be considered as a vascular surgical emergency. We report here our experience with this rare pathology.

Methods: At our hospital, we operated on 200 patients for abdominal aortic aneurysm over a 4-year period, and aortic dissection was the underlying pathology in eight of them. Diagnosis was based on history, imaging study findings and visualization at surgery.

Results: The mean size of the aorta at the time of diagnosis was 5.5 ± 0.4 cm. Aortic dissection was complicated by acute ischemia of lower limb and paraplegia in 1 patient and four patients were admitted to hospital with severe abdominal and back pain. Two patients with contained rupture were admitted with hemodynamic collapse and shock. One of the patients who presented with abdominal pain experienced also sudden onset paraplegia. The diagnosis of dissecting abdominal aortic aneurysm was established incidentally in the remaining 2 patients. All patients were treated using open techniques with paramedian transperitoneal incision. We performed aorto-bifemoral bypass operation procedure in all patients; there was no post-operative mortality in our series. One patient had to be reoperated because of bleeding during early postoperative period. One patient required transient dialysis at early postoperative period because of transient rise of serum creatinine level.

Conclusion: The surgical treatment of spontaneous abdominal aortic dissection is usually associated with low morbidity and mortality rates. However, the clinical form of presentation of acute abdominal aortic dissection is usually nonspecific, and diagnosis requires a high index of suspicion. (*Anadolu Kardiyol Derg 2008; 8: 286-90*)

Key words: Spontaneous abdominal aortic dissection, abdominal aortic aneurysm, cardiovascular surgical procedures

ÖZET

Amaç: Spontan abdominal aort disseksiyonu acil cerrahi gerektiren bir vasküler durum olarak düşünülmelidir. Biz bu çalışmada bu nadir patolojiyle ilgili tecrübelerimizi bildirdik.

Yöntemler: Hastanemizde 4 yıllık süre içinde abdominal aort anevrizması nedeniyle 200 hastayı opere ettik. Bunların 8 tanesinde altta yatan patoloji aort disseksiyonu idi. Tanı, hikaye, görüntüleme yöntemleri ve ameliyat sırasındaki gözleme dayalı idi.

Bulgular: Tanı konulduğu andaki ortalama aort çapı 5.5 ± 0.4 cm idi. Bir hastada disseksiyon komplikasyonu olarak alt ekstremitte iskemisi mevcuttu, 4 hasta ise hastaneye şiddetli akut karın ve sırt ağrısı ile başvurdu. Rüptürü olan iki hasta ise hemodinamik kollaps ve şok tablosu ile başvurdu. Karın ağrısı ile başvuran bir hastada ani başlangıçlı parapleji gelişti. Abdominal aort anevrizmasında disseksiyon 2 hastada tesadüfen saptandı. Bütün hastalar paramediyen transperitoneal insizyon ile açık ameliyat tekniği kullanılarak tedavi edildi. Yine bütün hastalara aorto-bifemoral baypas ameliyatı prosedürünü uyguladık. Serimizde ameliyat sonrası mortalitemiz yoktu. Bir hasta erken postoperatif dönemde kanamadan dolayı tekrar ameliyata alınmak zorunda kalındı. Bir hasta postoperatif erken dönemde serum kreatinin yüksekliğinden dolayı geçici diyalize gereksinim duydu.

Sonuç: Spontan abdominal aort disseksiyonu cerrahi tedavi ile düşük mortalite ve morbidite oranlarına sahiptir. Bununla birlikte akut abdominal disseksiyonun klinik formu nonspesiftir ve tanı için fazla ipucu gerektirir. (*Anadolu Kardiyol Derg 2008; 8: 286-90*)

Anahtar kelimeler: Spontan abdominal aort disseksiyonu, abdominal aort anevrizması, kardiyovasküler cerrahi işlemler

Introduction

Spontaneous dissection of the abdominal aorta is a rare pathology and may be associated with high morbidity and mortality rates. The disease usually occurs in male patients over the age of

fifty with a history of hypertension (1). These patients commonly present with sudden onset of severe abdominal and back pain. Deaths occur as a result of end organ ischemia or aortic rupture (1, 2).

Spontaneous dissection of the abdominal aorta is rare. It is accepted as a subgroup of aortic dissections. However, we could

not compare statistically the percentages of aortic dissections according to the localization due to our hospital's technical insufficiency. Furthermore, in all aortic aneurysms the percentage of spontaneous dissection of the abdominal aorta is 4 % in our series.

Isolated abdominal aortic dissection may be classified on the basis of etiology as spontaneous, iatrogenic or traumatic. The diagnosis of abdominal aortic dissection has been based on computed tomography, magnetic resonance, and angiography. They give the clinical specificity of its form of presentation. In this study, we present eight patients with abdominal aortic dissecting aneurysm who were treated successfully with open surgical techniques.

Methods

We operated on 200 patients with abdominal aortic aneurysm between November 2001 and September 2005. Eight cases of infrarenal abdominal aortic dissection were detected accounting for 4 % of total patients. These eight patients represent our study group. In all patients, clinical assessment, electrocardiogram and biochemical analysis were performed as an initial diagnostic work-up. The definitive diagnosis was established by using standard imaging modalities including ultrasonography (USG), contrasted or uncontrasted computed tomography (CT) and magnetic resonance imaging (MRI).

A thoracoabdominal CT scan with intravenous contrast was employed in all patients to establish the diagnosis. After the establishment of definitive diagnosis, all patients were firstly managed with anti-hypertensive medication including beta-blockers and after load reducing drugs. All patients were definitively shown not to have a concomitant thoracic aortic dissection (Fig. 1) and intimal flap starting just below the renal arteries and extending to iliac bifurcation (Fig. 2). Intramural hematoma was noted in 2 patients. All patients were treated using open techniques with paramedian transperitoneal incision. Suprarenal aortic free segment was used to control the infrarenal aorta. We exposed the proximal neck of aneurysmal sac by upward mobilization of the left renal vein. Following the control of distal end, the aorta was clamped and the sac was opened at the left

anterolateral aspect. The aorta was transected below the renal arteries. No dissection was noted in the proximal aorta. In all 8 patients the choice of procedure was aorto-bifemoral bypass operation. Bilateral iliac arteries were ligated below the iliac bifurcation. Mean aortic clamping time was 20 ± 6 min. During reconstruction of the proximal anastomosis, Teflon felts were used to secure homeostasis. The mean operation time was 100 ± 20 min. Following the completion of operation, all patients were transferred to intensive care unit and discharged from intensive care unit after the stabilization of hemodynamic status.

Statistical analysis

The descriptive statistics are given as mean \pm standard deviation.

Results

Eight patients with infrarenal abdominal aortic dissection were identified (Table 1). No one had a previous history of aortic surgery or intraaortic catheter and stenting procedure.

There were 7 men and 1 women with a mean age 62.5 ± 4.3 years old (range, 45 to 73 years) in the study group. Aortic dissection was complicated by acute ischemia with paraplegia of lower limb in 1 patient and four patients were admitted to hospital with severe abdominal and back pain. One of the patients who presented with abdominal pain experienced also sudden onset paraplegia. Two patients with contained rupture were admitted with hemodynamic collapse and shock. The diagnosis of dissecting abdominal aortic aneurysm was established incidentally in the remaining 2 patients. Tobacco use was present in 4 and hypertension was present in all eight patients. The dissection process was extending below the renal arteries to the iliac arteries in all patients. The mean size of the aorta at the time of diagnosis was 5.5 ± 0.4 cm. In 3 patients, we sent the biopsies for morphologic analysis. Histologic examination of these specimens were all aneurysmatic aortic wall structure.

There was no post-operative mortality in our series. One patient had to be reoperated because of bleeding during early postoperative period. One patient required transient dialysis at early postoperative period because of transient rise of serum creatinine level. Fortunately, the increase did not sustain more

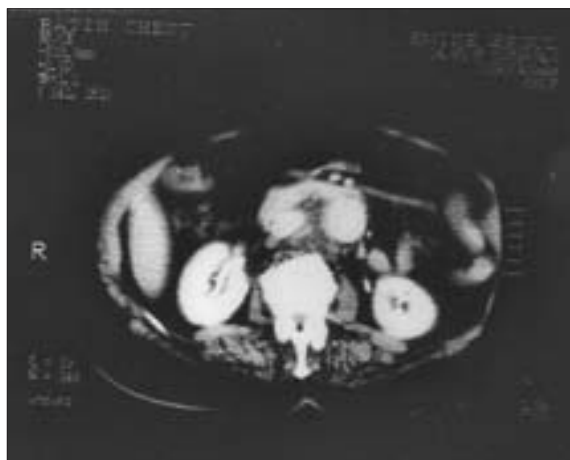

Figure 1. All patients were definitively shown not to have a concomitant thoracic aortic dissection

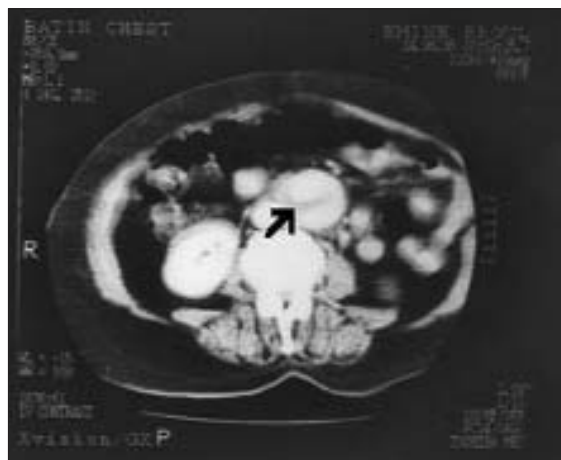


Figure 2. Computerized tomography scan revealed intimal flap starting just below the renal arteries and extending to iliac bifurcation

than 2 weeks. Mean duration of intensive care unit stay was 12.3 ± 7.5 hours (range, 5 to 22 h). The mean hospital stay was 7 ± 4.2 days (range, 6 to 11 days). Long-term follow-up was possible in all patients and mean duration of follow-up was 3.8 ± 0.7 years (range, 6 months to 5 years). One patient with preoperative paraplegia improved during postoperative period; but, lower extremity weakness continued at early follow-up period. At the end of 6-months physical rehabilitation, the patient was symptom free. All patients underwent CT scan 3 weeks after the surgical intervention (Fig. 3). All patients were free from symptomatic recurrence of malperfusion syndrome. There was no aneurysm or dissection formation in these 8 patients at late follow-up.

Discussion

Isolated spontaneous abdominal aortic dissection is an uncommon and poorly known pathology. It is produced by entry of blood into the tunica media resulting in a double lumen aorta. Systemic arterial hypertension is identified as the single most common factor predisposing to aortic dissection. Other causes include Marfan's syndrome, Ehlers Danlos' syndrome, aortic

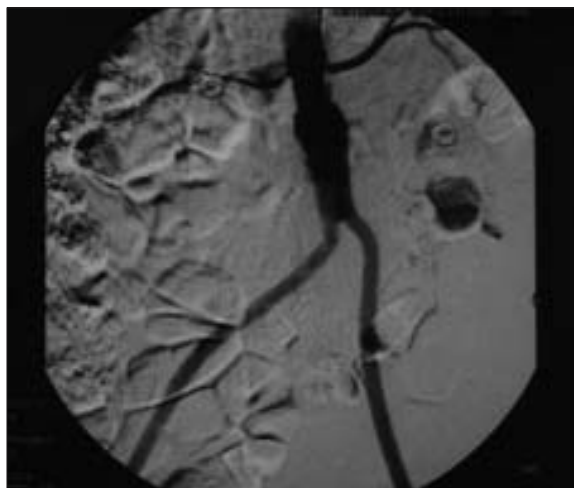


Figure 3. Postoperative control angiography of a patient who underwent aorto-bifemoral bypass procedure

coarctation, bicuspid aortic valve, aortic hypoplasia, cystic medial necrosis, pregnancy, trauma and iatrogenic causes. Traditionally, asymptomatic dissections are usually managed with aggressive antihypertensive therapy and follow-up carefully. But, the long term results demonstrated that up to 30-40 % of these patients will succumb to an aortic dissection-related death over a few year period (2). Patients presented with aortic dissection or rupture should be treated with emergent surgical aortic replacement procedure. Additionally, there is an approximately 25 % risk of a saccular aneurysm developing at the site of an unrepaired distal aortic dissection. However, we believe that mortality risk after surgical intervention is significantly less than that for descending thoracic aortic dissection (1-3).

Spontaneous infrarenal aortic dissection associated with abdominal aortic aneurysm is an indication for aortic repair, since their coexistence has been linked to a significant risk of aortic rupture (4).

Medical treatment is of better results than surgical repair in asymptomatic acute type B dissection patients. Hsu et al (5) reported 5-year survival rate of 98.9% with medical therapy. However, results of other ones were not so good. Juvonen et al (6) reported that the descending aorta of 20% to 28% of patients with chronic stable type B dissection will dilate and that 18% will eventually rupture during a period of 40 to 50 months. Xu et al (7) stated that early and mid term results showed that endovascular repair was effective in treatment of acute asymptomatic type B aortic dissection.

In our study, all patients we operated for acute abdominal aortic dissection were symptomatic and mean aortic diameter was 5.5 cm (Table 1). We think that in the treatment of asymptomatic abdominal aortic dissections (regardless of aortic diameter), endovascular repair should be considered like Xu et al (7).

Patients with abdominal aortic dissection may be presented with visceral malperfusion symptoms. Mortality of patients with renal ischemia is reported to be 50 to 70% and mortality figures in mesenteric ischemia can be as high as 87% (8, 9). The surgical mortality rates in patients with peripheral vascular ischemic complications also amounts to up to 87% of those with mesenteric ischemia with an 89% hospital mortality rate (8-11). In many cases, the inferior mesenteric artery was already occluded preoperatively. The most apparent cause for the colonic ischemia appears to be

Table 1. Patients characteristics

No.	Age	Sex	Symptoms	Aortic diameter, cm	Localizations of the intimal tearing	Procedure performed
1	45	M	Abdominal and back pain	6.2	Aortic and left iliac dissection	ABF
2	57	M	Right limb ischemia paraplegia	5.2	Aortic and right iliac dissection	ABF
3	65	M	Hemodynamic collapse	7.2	Aortic and left iliac dissection, contained rupture	ABF
4	58	F	Abdominal and back pain	5.1	Aortic and biiliac dissection	ABF
5	73	M	Hemodynamic collapse	5.5	Aortic and right iliac dissection, contained rupture	ABF
6	63	M	Abdominal and back pain, paraplegia	4.8	Aortic and biiliac dissection	ABF
7	62	M	Incidentally	5.1	Aortic and biiliac dissection	ABF
8	68	M	Incidentally	4.9	Aortic and biiliac dissection	ABF

ABF- aorto-bifemoral bypass, F-female, M-male

Table 2. The series in the literature

Author	Patients, n	Symptoms	Procedure performed
Farber A (1)	10	Abdominal pain	Direct aortic reconstruction
Becquemin J-P (2)	7	Acute back pain	Dacron tube graft interposition
Chang GQ (19)	8	Back pain	Stent-graft placement
Borioni R (20)	4	Abdominal pain	Bifurcated Dacron graft
Duebener LF (21)	10	Abdominal and chest pain	Endovascular stent grafting
Belov IuV (22)	7	Abdominal pain	Linear prosthesis of abdominal aorta
Busuttill S (23)	3	Abdominal pain	Direct aortic reconstruction

the sacrifice of the inferior mesenteric artery. In our cases backflow of inferior mesenteric arteries were sufficient, and we did not need any inferior mesenteric artery reimplantation.

Spontaneous healing of aortic dissection has been reported during medical therapy, but it is rarely occurring event since continuous flow through large entry tears seems to prevent spontaneous healing. The false lumen disappears and circumscriptive wall thickening develops (12-16). In the European Cooperative study wall thickening was observed as a sign of healing in only 4% of patients, mainly in type A (type II) and type B (type III) dissection (12). In MRI studies this was observed in 7% (17), by CT in 31% of type B (type III) dissections (18).

Replacement of a large segment of the aorta raises significant dangers of paraplegia from spinal cord devascularization. Operations for chronic dissection pose additional difficulties. Identification of branch vessels can be difficult. The dissected lumen must be opened widely in the abdominal aorta to allow identification and reimplantation of all visceral arteries. In case of less than total replacement of the aorta in chronic dissection, the intimal layer must be resected from the distal aortic cuff and the anastomosis done to the distal adventitial layer in order to avoid revascularization of organs supplied chronically from the false lumen.

Medical therapy is the initial line of treatment after the establishment of diagnosis. A resection of the diseased segment with prosthetic graft replacement is reported to give the best results. The literature data with this pathology are given in Table 2.

More recently, less invasive endovascular approaches have been proposed. These techniques are balloon fenestration and intraluminal stent procedures. Major risks of stent use include distal embolization and obstruction of branch vessels, leading to mesenteric or renal ischemia. Only small series have documented the use of these techniques; typically, they have identified high-risk surgical patients with complications of distal aortic dissections. Long-term data are not yet available and optimal patient selection for these procedures has not yet been described. Endovascular surgery was not considered as a treatment option due to patients were emergent and we did not have any endovascular surgery experience and also equipments.

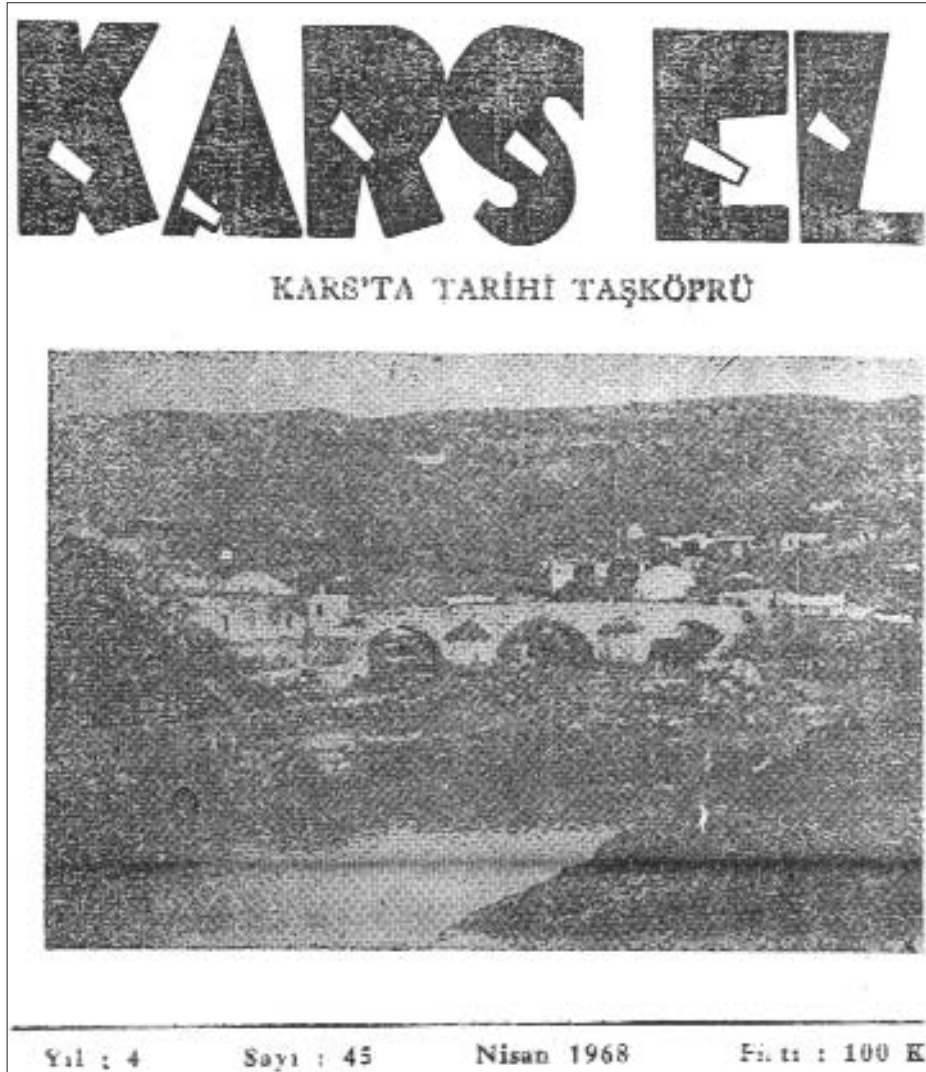Conclusion

The surgical treatment of spontaneous abdominal aortic dissection is usually associated with low morbidity and mortality rates. However, the clinical form of presentation of acute abdominal aortic dissection is usually nonspecific, and diagnosis requires a high index of suspicion.

References

- Farber A, Wagner WH, Cossman DV, Cohen JL, Walsh DB, Fillinger MF, et al. Isolated dissection of the abdominal aorta: clinical presentation and therapeutic options. *J Vasc Surg* 2002; 36: 205-10.
- Becquemin J-P, Dleuze P, Watelet J, Testard J, Melliére D. Acute and chronic dissections of the abdominal aorta: clinical features and treatment. *J Vasc Surg* 1990; 11: 397-402.
- DeBaakey ME, McCollum CH, Crawford ES, Morris GC Jr, Howell J, Noon GP, et al. Dissection and dissecting aneurysms of the aorta: twenty-year follow-up of five hundred twenty seven patients treated surgically. *Surgery* 1982; 92: 1118-33.
- Cambria RP, Brewster DC, Moncure AC, Steinberg FL, Abbott WM. Spontaneous aortic dissection in the presence of coexistent or previously repaired atherosclerotic aortic aneurysm. *Ann Surg* 1988; 208: 619-24.
- Hsu RB, Ho YL, Chen RJ, Wang SS, Lin FY, Chu SH. Outcome of medical and surgical treatment in patients with acute type B aortic dissection. *Ann Thorac Surg* 2005; 79: 780-5.
- Juvonen T, Ergin MA, Galla JD, Lansman SL, McCullough JN, Nguyen K, et al. Risk factors for rupture of chronic type B dissections. *J Thorac Cardiovasc Surg* 1999; 117: 776-86.
- Xu SD, Huang FJ, Yang JF, Li ZZ, Wang XY, Zhang ZG, et al. Endovascular repair of acute type B aortic dissection: Early and mid-term results. *J Vasc Surg* 2006; 43: 1090-5.
- Elefteriades JA, Hartleroad J, Gusberg RJ, Salazar AM, Black HR, Kopf GS, et al. Long-term experience with descending aortic dissection: the complication-specific approach. *Ann Thorac Surg* 1992; 53: 11-20.
- Miller DC, Mitchell RS, Oyer PE, Stinson EB, Jamieson SW, Shumway NE. Independent determinants of operative mortality for patients with aortic dissections. *Circulation* 1984; 70: 153-64.
- Cambria RP, Brewster DC, Gertler J, Moncure AC, Gusberg R, Tilson MD, et al. Vascular complications associated with spontaneous aortic dissection. *J Vasc Surg* 1988; 7: 199-209.
- Laas J, Heinemann M, Schaefer HJ, Daniel W, Borst HG. Management of thoracoabdominal malperfusion in aortic dissection. *Circulation* 1991; 84: III20-4.
- Erbel R, Oelert H, Meyer J, Puth M, Mohr-Katoly S, Hausmann D, et al. Influence of medical and surgical therapy on aortic dissection evaluated by transesophageal echocardiography. *Circulation* 1993; 87: 1604-15.
- Mohr-Kahaly S, Erbel R, Rennollet H, Wittlich N, Drexler M, Oelert H, et al. Ambulatory follow-up of aortic dissection by transesophageal two-dimensional and color-coded Doppler echocardiography. *Circulation* 1989; 80: 24-33.
- Erbel R, Bednarczyk I, Pop T, Todt M, Henrichs KJ, Brunier A, et al. Detection of dissection of the aortic intima and media after angioplasty of coarctation of the aorta. An angiographic, computer tomographic, and echocardiographic comparative study. *Circulation* 1990; 81:805-14.

15. Alfonso F, Almeria C, Fernandez-Ortiz A, Segovia J, Ferreiros J, Goicolea J, et al. Aortic dissection occurring during coronary angioplasty: angiographic and transesophageal echocardiographic findings. Cathet Cardiovasc Diagn 1997; 42: 412-5.
16. Wigle RL, Moran JM. Spontaneous healing of a traumatic thoracic aortic tear: case report. J Trauma 1991; 31: 280-3.
17. Di Cesare E, Di Renzi P, Pavone P, Marsili L, Castallo F, Passariello R. Postsurgical follow-up of aortic dissections by MRI. Eur J Radiol 1991; 13: 27-30.
18. Hara K, Yamaguchi T, Wanibuchi Y, Kurokawa K. The role of medical treatment of distal type aortic dissection. Int J Cardiol 1991; 32: 231-40.
19. Chang GQ, Wang SM, Li XX, Hu ZJ, Yao C, Yin HH. Single or staged endovascular stent-graft repair for aortic dissection with multi-tears. Zhonghua Wai Ke Za Zhi 2005; 43:866-9.
20. Borioni R, Garofalo M, De Paulis R, Nardi P, Scaffa R, Chiariello L. Abdominal Aortic dissections: anatomic and clinical features and therapeutic options. Tex Heart Inst J 2005; 32: 70-3.
21. Duebener LF, Lorenzen P, Richardt G, Misfeld M, Notzold A, Hartmann F, et al. Emergency endovascular stent-grafting for life-threatening acute type B aortic dissections. Ann Thorac Surg 2004; 78: 1261-7.
22. Belov luV, Stepanenko AB, Gens AP, Zverkhanovskaia TN. Dissection and dissected aneurysm of the abdominal aorta. Khirurgiia 2004; 5: 52-6.
23. Busuttill S, Hall L, Hines GL. Spontaneous dissection of the abdominal aorta: experience with five patients. Ann Vasc Surg 1993; 7: 414-8.



Sayın Dr. Budak Demiral'ın arşivinden.