

7. Hind CR, Wong CM. Detection of pulmonary arteriovenous fistulae in patient with cirrhosis by contrast 2D echocardiography. Gut 1981; 22: 1042-4.
8. Bay A, Öner AF, Etiik Ö, Köseoğlu B, Kaya A. Unusual presentation of infantile hemangioendothelioma. Pediatr Blood Cancer 2005; 44: 267-9.
9. Woltering MC, Robben S, Egeler RM. Hepatic hemangioendothelioma of infancy: treatment with interferon alpha. J Pediatr Gastroenterol Nutr 1997; 24: 348-51.
10. Kasahara M, Kiuchi T, Haga H, Uemoto S, Uryuhara K, Fujimoto Y, et al. Monosegmental living-donor liver transplantation for infantile hepatic hemangioendothelioma. J Pediatr Surg 2003; 38: 1108-11.

**Address for Correspondence/Yazışma Adresi:** Dr. Sonay Incesoy Özdemir  
Clinic of Pediatric Oncology, Dr. Sami Ulus Children's Hospital, Ankara, Turkey  
Phone: +90 312 330 81 67 Fax: +90 312 317 03 53 E-mail: sinesoy@yahoo.co.uk  
**Available Online Date/Çevrimiçi Yayın Tarihi:** 01.03.2011

©Telif Hakkı 2011 AVES Yayıncılık Ltd. Şti. - Makale metnine www.anakarder.com web sayfasından ulaşılabilir.

©Copyright 2011 by AVES Yayıncılık Ltd. - Available on-line at www.anakarder.com  
doi:10.5152/akd.2011.043

## Echocardiographic diagnosis of atrioventricular septal defect without primum atrial septal defect: a relatively "common" congenital heart defect in Down's syndrome

*Primum atriyal septal defekt olmaksızın, atriyoventriküler septal defektin ekokardiyografik tanısı: Down sendromunda görece "yaygın" konjenital kalp defekti*

**Sulafa Ali**

**Department of Pediatric Cardiology, Faculty of Medicine,  
University of Khartoum, Khartoum, Sudan**

### Introduction

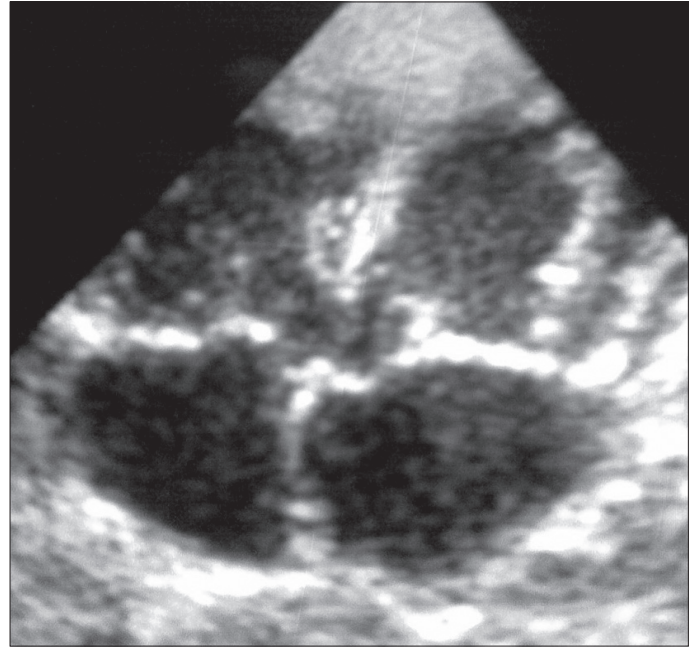
Atrioventricular septal defects (AVSD) are congenital heart defects characterized by a common atrioventricular (AV) junction guarded by an abnormal valve with variable presence of primum atrial septal defects (ASD) and inlet ventricular septal defects (VSD) (1). A less common form of AVSD occurs when the common leaflet is fused to either the atrial septum or to the crest of the ventricular septum, creating an AVSD with no interatrial or interventricular communications respectively. There have been case reports of AVSD with intact septa, where the diagnosis was made at necropsy (2). In 2005, we validated quantitative echocardiographic measurements that helped in diagnosing of AVSD with no primum ASD: the measurements of the left ventricle inlet to outlet distance ratio and the percentage of the left AV valve guarded by the mural leaflet (3). In this report we describe four more cases of AVSD without primum ASD diagnosed using the above echocardiographic measurements.

### Case Report

Four patients with AVSD and intact atrial septum were identified out of 50 patients with Down's syndrome and AVSD (3.7%).

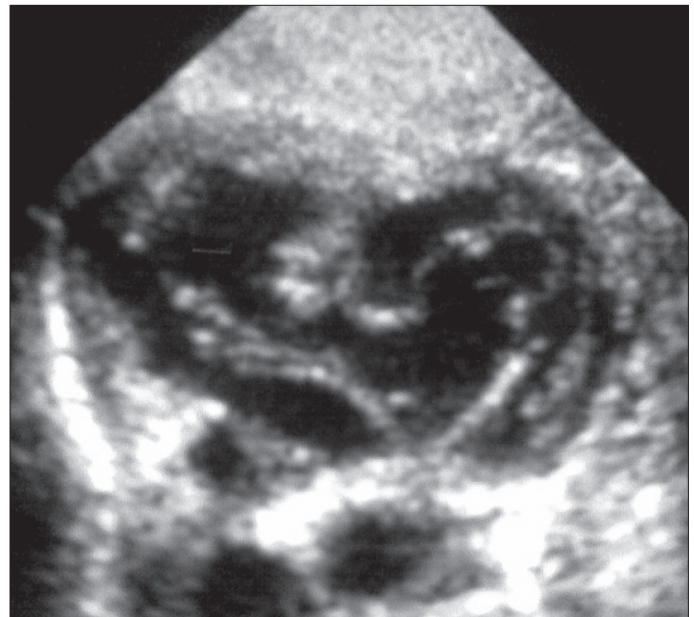
All four patients were males. Their ages were 2, 3, 12 and 36 months. They all presented with shortness of breathing and failure to thrive. In all patient's physical examination revealed signs of congestive heart failure which was mild in the 36-month-old patient. Echocardiographic examination was done and revealed the following:

1. A large inlet VSD
2. No primum ASD (Fig. 1)
3. A common atrioventricular (AV) junction with a common AV valve (Fig. 2)
4. The percentage of the left AV valve guarded by the mural leaflet was 30-40 (Fig. 3A and B)



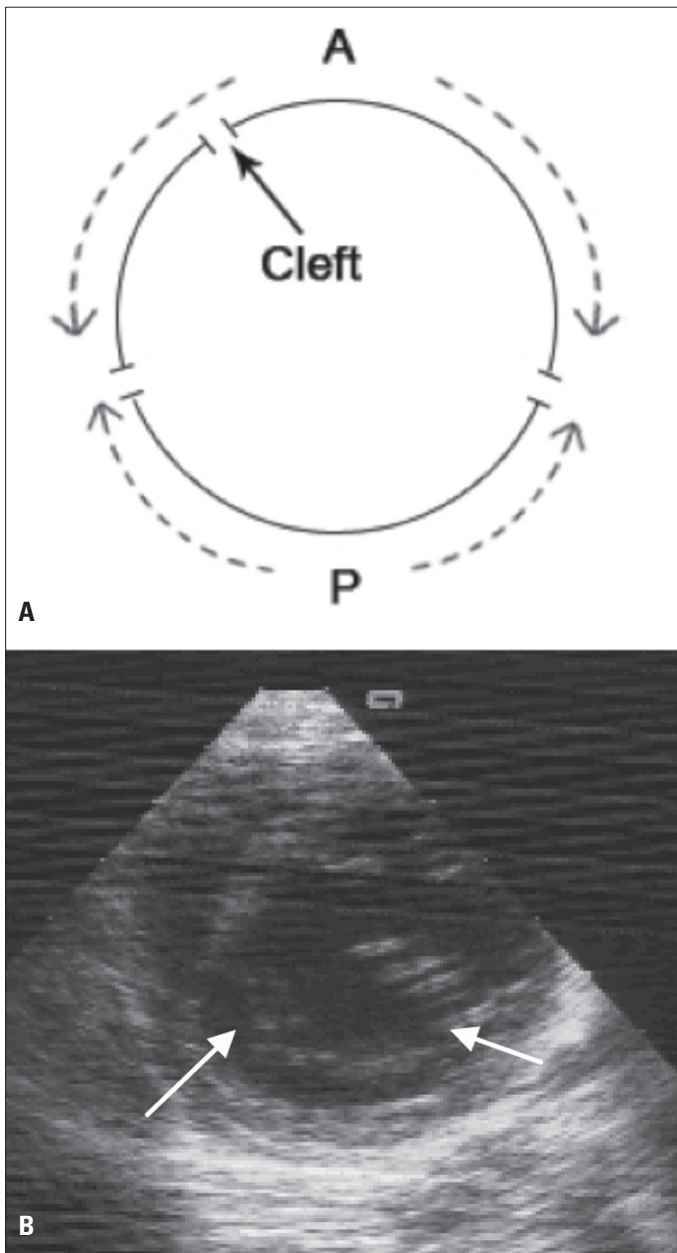
**Figure 1. A four -chamber echocardiographic view showing a large inlet VSD with no primum ASD. Abnormal AV valve noted**

ASD - atrial septal defect, AV - atrioventricular, VSD - ventricular septal defect



**Figure 2. En-face view of the same patient in Figure 1 showing a common AV junction with a small mural leaflet occupying 32% of the left AV valve orifice**

AV - atrioventricular



**Figure 3. A)** A diagram showing measurement of the percentage of the left AVV guarded by the posterior leaflet, P is posterior leaflet circumference measured from commissure to commissure, A (anterior leaflet circumference) measured with bridging of the pseudo cleft (arrow)  
**B)** A parasternal short axis view at the level of the left AV valve showing a small mural leaflet (arrows) occupying 34% of the valve orifice. A large pseudo cleft is seen

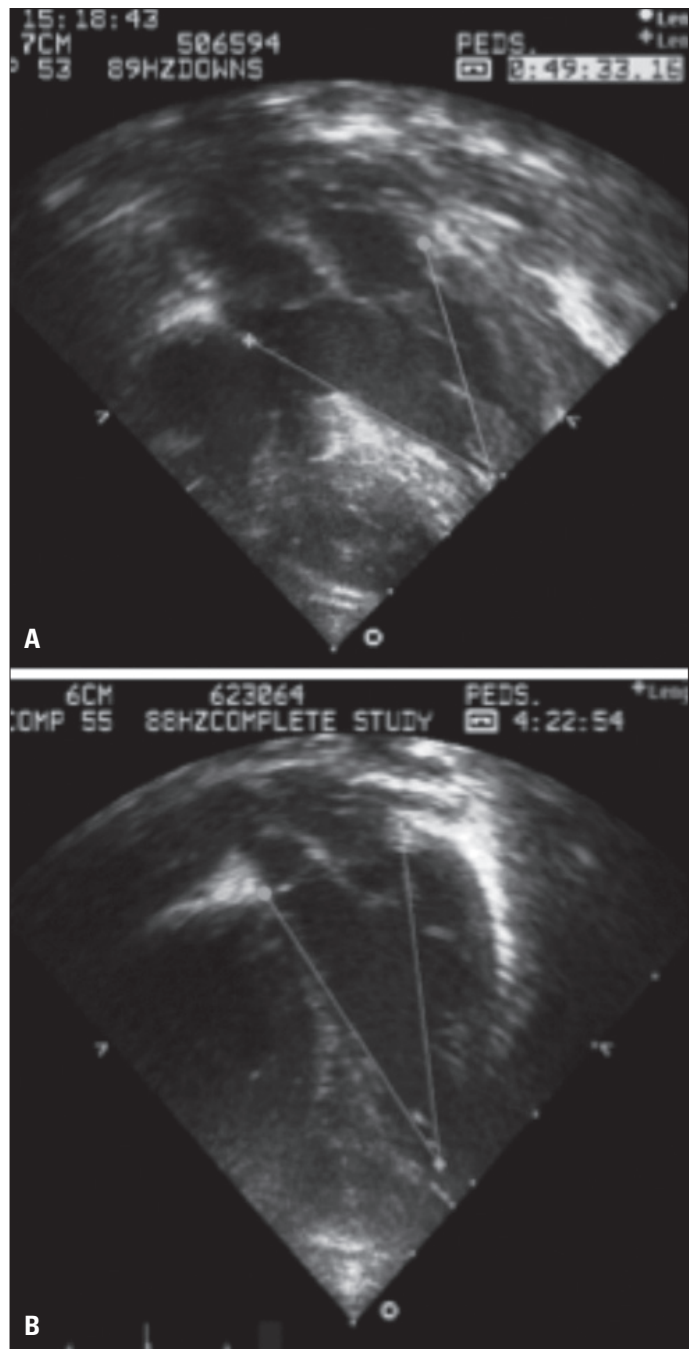
AVV - atrioventricular valve, AV - atrioventricular

5. The left ventricle inlet/outlet ratio was 0.7-0.8:1 (Fig. 4A and B)
6. A competent AV valve

#### Diagnosis of AVSD

AVSD was diagnosed with the following criteria and measurements:

1. The presence of a common AV junction from the subcostal (en-face) view.
2. The morphology of the left AV valve:
  - i. Presence of a tri-leaflet appearance with the presence of a 'pseudo cleft'.



**Figure 4. A)** A four -chamber with aorta echocardiographic view in a normal patient showing measurement of left ventricle inlet to outlet ratio of 1:1 **B)** A four - chamber with aorta echocardiographic view in a patient with AVSD showing inlet to outlet ratio of 0.8:1

AVSD - atrioventricular septal defect

ii. Calculation of the percentage of the left AV valve that is guarded by the posterior (mural) leaflet of 44 or less. This was measured from the parasternal short axis or the subcostal views at the level of the left AVV when it was fully open and the two commissures were clearly visible. The circumferences of the anterior leaflet (A) and the posterior leaflet (P) were measured. A+P=the circumference of the left AVV valve.

$$\text{The percentage of the left AV valve guarded by the mural leaflet} = \frac{P}{(A+P)} \times 100$$

The commissure between the two bridging leaflets (cleft) was bridged and measured as one leaflet (Fig. 3 A).

3. Measurement of left ventricle inlet/outlet ratio equal to or less than 0.88: 1. This measurement was performed in the parasternal long-axis or 4 chamber views in diastole. The inlet distance was measured from the insertion of the posterior mitral valve/left AVV leaflet in the posterior left ventricular wall to a midpoint in the left ventricular apex. The outlet distance was measured from the anterior edge of the aortic valve annulus to the same point in the left ventricle apex (Fig. 4 A).

## Discussion

The diagnosis of AVSD especially when associated with a condition requiring surgery is extremely important because the position of conduction axis in AVSD is different from normal (4). Missing the diagnosis of AVSD can lead to reoperation for left AVV regurgitation, as the valve can be competent at the time of the first surgery.

Recently, AVSD with intact septal structures had been identified echocardiographically in 6 patients by Kaski et al. (5) and in a further patient by Croti et al. (6). We previously reported that in Sudanese patients with Down's syndrome AVSD was present in 48% of patients with one case of intact atrial septum (7). In this case series AVSD with intact atrial septum represented 3.7% of patients with Down's syndrome who had AVSD and this suggests that this diagnosis is not rare. The identification of a common AV junction from the subcostal view had been the gold standard for diagnosis of AVSD in all the previous reports. However patients with "isolated" mitral cleft especially when associated with a VSD can have accessory chordae attached to the interventricular septum giving the impression of a common AV valve junction. In addition, the en face view is not routinely used for patients leading to the erroneous diagnosis of isolated VSD. In this report, we used additional echocardiographic measurements: the left ventricle inlet: outlet ratio and the percentage of the left AV valve that is guarded by the mural leaflet and proved their value in diagnosis of AVSD with no primum ASD. We observed that measurement of the mural leaflet of the left AVV is relatively easy and more sensitive than the inlet outlet ratio. The fact that the short-axis view of the left AVV is routinely done gives this measurement more advantage over the en face view demonstration of a common AV valve junction. We believe that these measurements can also be applied in patients with AVSD and intact interventricular septum. Our study is limited by the fact that surgery had not been performed yet; we need to alert the surgeon to look carefully for the presence of a small primum ASD.

## Conclusion

These two echocardiographic measurements are valuable in diagnosing AVSD with intact septa. We think that AVSD with no primum ASD is not rare in patients with Down's syndrome.

## Acknowledgement

We would like to thank Miss Alaa Ahmed Musa for preparation of the diagram.

## References

1. Jacobs JP, Burke RP, Quintessenza JA, Mavroudis C. Congenital Heart Surgery Nomenclature and Database Project: atrioventricular canal defect. *Ann Thorac Surg* 2000; 69: 36-43.
2. Silverman NH, Ho SY, Anderson RH, Smith A, Wilkinson JL. Atrioventricular septal defect with intact atrial and ventricular septal structures. *Int J Cardiol* 1984; 5: 567-73.
3. Sulafa AK, Tamimi O, Najm HK, Godman MJ. Echocardiographic differentiation of atrioventricular septal defects from inlet ventricular septal defects and mitral valve clefts. *Am J Cardiol* 2005; 5: 607-10.
4. Seo JW, Zuberbuhler JR, Ho SY, Anderson RH. Surgical significance of morphological variations in the atrial septum in atrioventricular septal defect for determination of the site of penetration of the atrioventricular conduction axis. *J Card Surg* 1992; 7: 324-32.
5. Kaski JP, Wolfenden J, Josen M, Daubeney PE, Shinebourne EA. Can atrioventricular septal defects exist with intact septal structures? *Heart* 2006; 92: 832-5.
6. Croti UA, De Marchi CH, Aiello VD. Atrioventricular septal defect with intact septal structures presenting as left atrioventricular valvar insufficiency. *Cardiol Young* 2006; 16: 92-4.
7. Ali SK. Cardiac abnormalities of Sudanese patients with Down's syndrome and their short-term outcome. *Cardiovasc J Afr* 2009; 20: 112-5.

**Address for Correspondence/Yazışma Adresi:** Dr. Sulafa Ali  
Department of Pediatric Cardiology, Faculty of Medicine, University of Khartoum,  
Khartoum, Sudan  
Phone: +000249 918075694 E-mail: sulafakhalid2000@yahoo.com  
**Available Online Date/Çevrimiçi Yayın Tarihi:** 01.03.2011

©Telif Hakkı 2011 AVES Yayıncılık Ltd. Şti. - Makale metnine [www.anakarder.com](http://www.anakarder.com) web sayfasından ulaşılabilir.

©Copyright 2011 by AVES Yayıncılık Ltd. - Available on-line at [www.anakarder.com](http://www.anakarder.com)  
doi:10.5152/akd.2011.044