

- Glicklich D, Figura I. Vancomycin and cardiac arrest. Ann Intern Med 1984; 101: 880.
- Mayhew JF Deutsch S. Cardiac arrest following administration of vancomycin. Can Anaesth Soc J 1985; 32: 65-6. [CrossRef]
- Dajee H, Laks H, Miller J, Oren R. Profound hypotension from rapid vancomycin administration during cardiac operation. J Thorac Cardiovasc Surg 1984; 87: 145-6.
- Boussemart T, Cardona J, Berthier M, Chevrel J, Oriot D. Cardiac arrest associated with vancomycin in a neonate. Arch Dis Child Fetal Neonatal Ed 1995; 73: 123. [CrossRef]

Yazışma Adresi/Address for Correspondence: Dr. Nurettin Yeral
Mustafa Kemal Üniversitesi Tıp Fakültesi, Araştırma ve Uygulama Hastanesi,
Kardiyoloji Anabilim Dalı, Hatay- Türkiye
Tel: +90 326 263 85 34 Faks: +90 284 513 40 20
E-posta: dryeral@hotmail.com

Çevrimici Yayın Tarihi/Available Online Date: 13.03.2012

©Telif Hakkı 2012 AVES Yayıncılık Ltd. Şti. - Makale metnine www.anakarder.com web sayfasından ulaşılabilir.

©Copyright 2012 by AVES Yayıncılık Ltd. - Available on-line at www.anakarder.com
doi:10.5152/akd.2012.074

A 13-year-old boy with a short QT interval

Onüç yaşındaki bir erkek çocukta saptanan kısa QT intervali

Introduction

Short QT interval syndrome (SQTS) is a familial clinical-electrocardiographic disorder that was first described by Gussak et al. (1) in 2000. A definitive link between SQTS and familial SCD was described by Gaita et al. (2) in 2003. The electrocardiogram (ECG) is characterized by an abnormally short QT interval, typically less than 320 ms with tall-peaked, narrow, symmetrical T waves. The diagnosis of SQTS can be made when the characteristic ECG findings are present, and it should be suspected in the presence of a family history of SCD, unexplained syncope or ventricular fibrillation. We report a case with a very short QT interval (300 ms) without any history of major cardiac events.

Case Report

A 13-year-old boy was admitted to our department because of repetitive chest pain. His pain was not associated with palpitation, exercise, syncope or pre-syncope. ECG showed a sinus rhythm at 62 bpm with a QT interval of 280 ms, QTc interval of 300 ms and morphologically abnormal T-waves that were symmetric, tall, and narrow with an absent ST segment (Fig. 1). The chest X-ray was normal. Echocardiography showed a small septum secundum atrial defect. The biochemical markers were within normal limits. A 24-hour Holter recording revealed an underlying sinus rhythm, with heart rates between 48 to 153 bpm and no ventricular ectopy. A treadmill exercise test was normal. The electrophysiological study revealed normal atrial and ventricular effective refractory periods (230 ms and 170 ms respectively) without any inducible fibrillations. Although the family history was susceptible for sudden cardiac death, he was free of arrhythmia symptoms and denied any syncope or presyncope episodes. His mater-

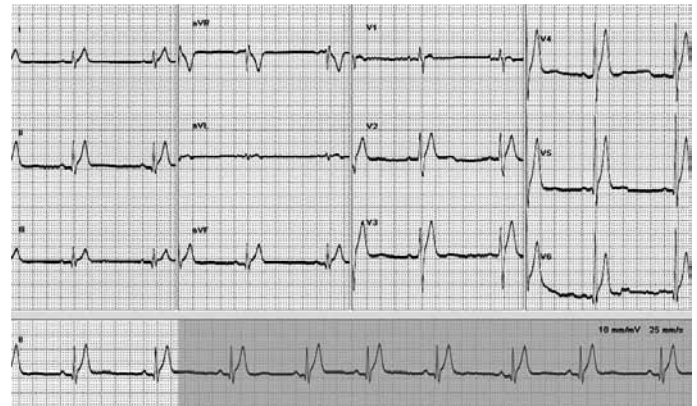


Figure 1. ECG with short QT interval (QTc=300 ms) and tall peaked T waves
ECG - electrocardiogram

nal uncle had died suddenly at the age of 28 years with a possible diagnosis of myocardial infarction but any record of ECG was not present and history of symptoms of arrhythmia had not been learned. Family screening with ECGs revealed that his mother, father and sister had T-waves that were morphologically identical to his, with tall, symmetric, peaked T-waves. His mother's QT interval was 320 ms. However, the QT intervals of his father and sister ranged from 360 to 400 ms. All of them were clinically asymptomatic. In light of this history, this case was provisionally diagnosed as short QT interval rather than SQTS, and the patient has not yet been treated with any medication.

Discussion

Short QT syndrome is a rare form of hereditary channelopathy with an abnormally short QT interval and a high propensity to atrial and ventricular fibrillation. The genetic inheritance pattern is autosomal-dominant with a positive family history of sudden cardiac death. To date, three principal genetic mutations in different potassium ion channels and two mutations in the L-type calcium channel have been linked to the syndrome (3, 4). If a patient has a short QT interval, positive genetic testing will be able to confirm the diagnosis. However, genetic testing could not be performed in our case.

SQTS has been described in a limited number of patients. Initially, a diagnosis of SQTS was considered only in patients with a QT interval of 300 milliseconds or less, but later a similar clinical picture was observed in some people with slightly longer QT intervals. In published reports of patients with SQTS, the duration of the QT interval has been reported to be between 210 and 340 milliseconds. Recent epidemiological studies have shown no cases of QTc<330 ms among 12.012 healthy subjects (5), no cases of QTc<350 ms among 19.153 healthy subjects (6) and only 11 cases of QTc<320 ms and 43 cases of QTc<340 ms in a middle-aged Finnish population of 10.822 (7). As reported by Gaita et al. (2), the disease may be underestimated to date because no reports have related a short QT interval to malignant arrhythmias; hence, sudden death may be the first clinical manifestation in otherwise healthy subjects, thus preventing ECG observation.

In recent years, a QTc less than 320 milliseconds has been definitely accepted as abnormal in the general population; however, Anttonen et al. (7) have reported that a short QT interval was not associated with life-threatening cardiac events. This lack of association between an abnormally shortened QTc interval and cardiac events has been confirmed by another study from Japan (8). Consequently, the short QT interval in SQTS seems to be a phenotypic expression lacking an association with arrhythmia risk, as suggested by Couderec and Coeli (9).

There have been few pediatric SQTS cases described in the literature. The first clinical report of SQTS described a 17-year-old female with atrial fibrillation and a QTc interval of 280 ms (1). Villlalfane et al. (10) collected data on 10 pediatric patients from 8 families with SQTS (QTc ranging from 252 to 320 ms).

Although his family history was suspect for sudden cardiac death, our patient was free of arrhythmia symptoms and denied any syncope or presyncope and he has normal atrial (230 ms) and near-normal ventricular refractory periods (170 ms) without any inducible fibrillations in the electrophysiological study. In light of these considerations, he was diagnosed as having idiopathic short QT intervals rather than SQTS and has not yet been treated with pharmacological therapy, such as quinidine, or an implantable cardioverter-defibrillator (ICD). This is the first described case with short QT interval in childhood in Turkey.

Conclusion

As in previous reports, we suggest that a short QT interval on a 12-lead ECG does not by itself predict increased risk of life-threatening arrhythmias (7). But it should be taken into consideration for each patient, and screening for a short QT interval using a routine ECG should be performed in subjects with atypical syncope, survivors of sudden cardiac death and any young patient with idiopathic atrial or ventricular fibrillation.

Kadir Babaoğlu, Köksal Binnetoğlu, Gürkan Altun, Volkan Tuzcu¹
Department of Pediatric Cardiology, Faculty of Medicine, Kocaeli University, Kocaeli
¹Clinic of Pediatric Cardiology, Mehmet Akif Ersoy Thoracic and Cardiovascular Surgery Center and Research Hospital, İstanbul-Turkey

References

1. Gussak I, Brugada P, Brugada J, Wright RS, Kopecky SL, Chaitman BR, et al. Idiopathic short QT interval: a new clinical syndrome? *Cardiology* 2000; 94: 99-102. [\[CrossRef\]](#)

2. Gaita F, Giustetto C, Bianchi F, Wolpert C, Schimpf R, Riccardi R, et al. Short QT Syndrome: a familial cause of sudden death. *Circulation* 2003; 108: 965-70. [\[CrossRef\]](#)
3. Bellocq C, van Ginneken AC, Bezzina CR, Alders M, Escande D, Mannens MM, et al. Mutation in the KCNQ1 gene leading to the short QT-interval syndrome. *Circulation* 2004; 109: 2394-7. [\[CrossRef\]](#)
4. Antzelevitch C, Pollevick GD, Cordeiro JM, Casis O, Sanguinetti MC, Aizawa Y, et al. Loss-of-function mutations in the cardiac calcium channel underlie a new clinical entity characterized by ST-segment elevation, short QT intervals, and sudden cardiac death. *Circulation* 2007; 115: 442-9. [\[CrossRef\]](#)
5. Gallagher MM, Magliano G, Yap YG, Padula M, Morgia V, Postorino C, et al. Distribution and prognostic significance of QT intervals in the lowest half centile in 12,012 apparently healthy persons. *Am J Cardiol* 2006; 98: 933-5. [\[CrossRef\]](#)
6. Moriya M, Seto S, Yano K, Akahoshi M. Two cases of short QT interval. *Pacing Clin Electrophysiol* 2007; 30: 1522-6. [\[CrossRef\]](#)
7. Anttonen O, Junttila MJ, Rissanen H, Reunanen A, Viitasalo M, Huikuri HV. Prevalence and prognostic significance of short QT interval in a middle-aged Finnish population. *Circulation* 2007; 116: 714-20. [\[CrossRef\]](#)
8. Funada A, Hayashi K, Ino H, Fujino N, Uchiyama K, Sakata K, et al. Assessment of QT intervals and prevalence of short QT syndrome in Japan. *Clin Cardiol* 2008; 31: 270-4. [\[CrossRef\]](#)
9. Couderc JP, Lopes CM. Short and long QT syndromes: does QT length really matter? *J Electrocardiol* 2010; 43: 396-9. [\[CrossRef\]](#)
10. Villalfane J, Young ML, Maury P, Wolpert C, Anttonen O, Hamilton R, et al. Short QT syndrome in a pediatric patient. *Pediatr Cardiol* 2009; 30: 846-50. [\[CrossRef\]](#)

Address for Correspondence/Yazışma Adresi: Dr. Kadir Babaoğlu
Kocaeli Üniversitesi Tıp Fakültesi, Pediyatrik Kardiyoloji Bölümü,
Kocaeli-Türkiye
Phone: +90 262 303 80 35 Fax: +90 262 303 80 03
E-mail: babaogluk@yahoo.com

Available Online Date/Çevrimiçi Yayın Tarihi: 13.03.2012

©Telif Hakkı 2012 AVES Yayıncılık Ltd. Şti. - Makale metnine www.anakarder.com web sayfasından ulaşılabilir.

©Copyright 2012 by AVES Yayıncılık Ltd. - Available on-line at www.anakarder.com
doi:10.5152/akd.2012.075