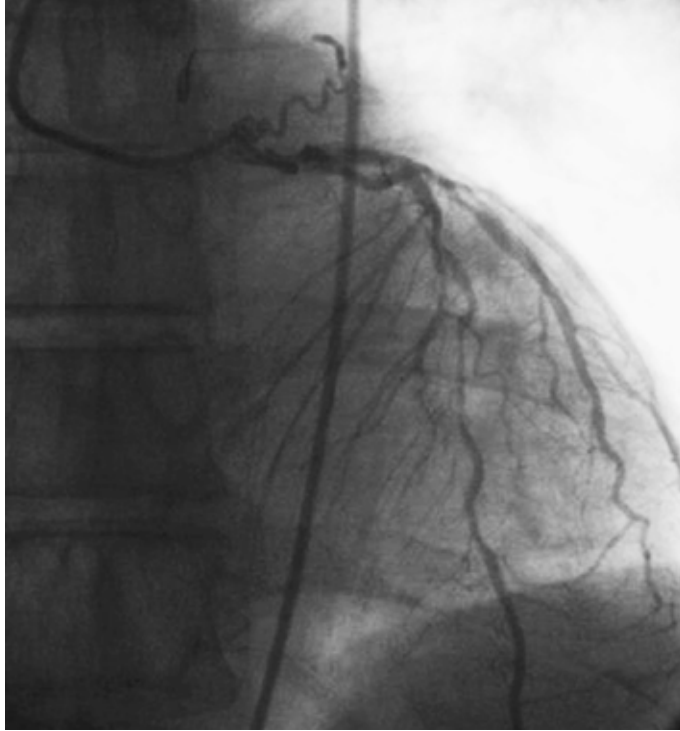
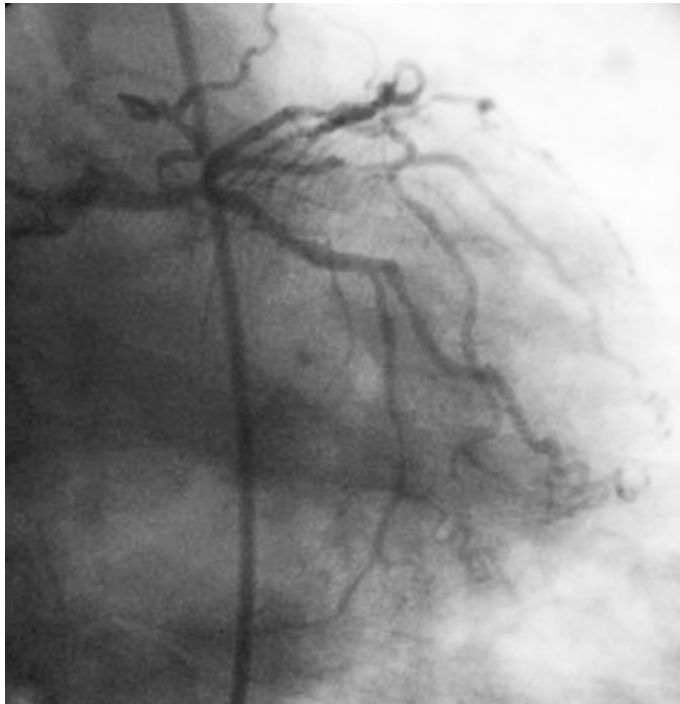
anjyografisinde sol ana koroner arterde, sol ön inen arterde, sirkumfleks arterde ve sağ koroner arterde kritik lezyonları mevcuttu (Şekil 1, 2, Video 1-4. Video/hareketli görüntüler www.anakarder.com' da izlenebilir). Ayrıca sol ana koroner arterden köken alıp pulmoner artere dökülen fistül tespit edildi (Şekil 1, 2, Video 1-4. Video/hareketli görüntüler www.anakarder.com' da izlenebilir). Hastaya koroner arter baypas cerrahisi ve fistül ligasyonu önerildi.



Şekil 1. Yaygın koroner arter hastalığına eşlik eden sol ana koroner arterden köken alıp pulmoner artere dökülen fistül izlenmektedir



Şekil 2. Fistülün sol ana koroner arterden köken aldığı izlenmektedir

- Video 1.** Sol koroner anjiyografi, anterior-posteriyor görüntü
Video 2. Sol koroner anjiyografi, sağ kaudal görüntü
Video 3. Sol koroner anjiyografi, anterior-posteriyor kaudal görüntü
Video 4. Sağ koroner anjiyografi, sol anterior oblik görüntü

**Muhammet Raşit Sayın, Mehmet Ali Çetiner, Turgut Karabağ,
Sait Mesut Doğan, Mustafa Aydın**
Zonguldak Karaelmas Üniversitesi Tıp Fakültesi, Kardiyoloji
Anabilim Dalı, Zonguldak-Türkiye

Yazışma Adresi/Address for Correspondence: Dr. Muhammet Raşit Sayın
Zonguldak Karaelmas Üniversitesi Tıp Fakültesi, Kardiyoloji Anabilim Dalı,
Zonguldak-Türkiye

Tel: +90 372 261 21 62 Faks: +90 372 261 01 55

E-posta: sayinmr@mynet.com

Çevrimiçi Yayın Tarihi/Available Online Date: 13.04.2012

©Telif Hakkı 2012 AVES Yayıncılık Ltd. Şti. - Makale metnine www.anakarder.com web sayfasından ulaşılabilir.

©Copyright 2012 by AVES Yayıncılık Ltd. - Available on-line at www.anakarder.com
doi:10.5152/akd.2012.114

Pericardial cyst: a rare cause of recurrent palpitation episodes

Perikardiyal kist: Tekrarlayan çarpıntı ataklarının nadir bir nedeni

A 37-year-old woman with no previous cardiovascular disease presented with palpitation. She described recurrent palpitation episodes for 6 months. Examination was unremarkable except arrhythmic pulse. Electrocardiogram revealed atrial fibrillation with high ventricular rate. Chest X-ray revealed an opacity adjacent to right heart borders (arrow).

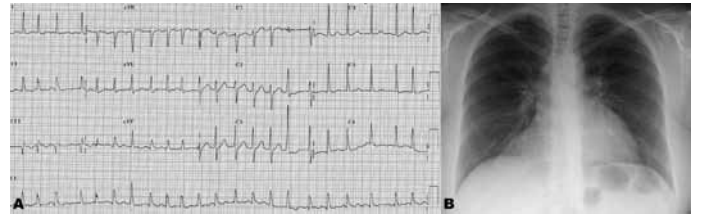


Figure 1. A) Electrocardiogram showing atrial fibrillation with high ventricular rate (140 bpm). B) Chest X-ray image of an opacity adjacent to right heart borders (arrow)

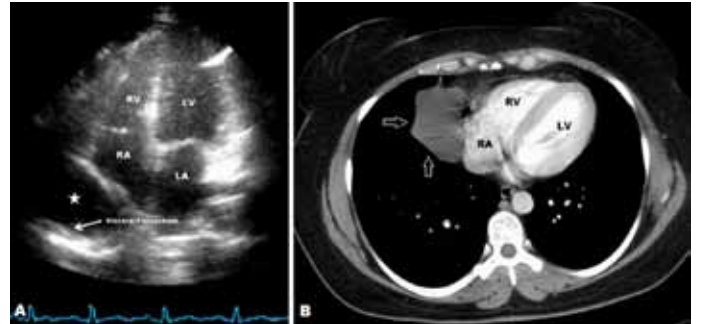


Figure 2. A) Transthoracic echocardiography apical four-chamber view of an echo-free space behind right atrium (star). B) Computed tomography view of a large fluid attenuation mass consistent with pericardial cyst (arrow)

LA - left atrium, LV - left ventricle, RA - right atrium, RV - right ventricle

lar rate (140 bpm) (Fig. 1A). A chest X-ray revealed smoothly marginated opacity in the region of the right cardiophrenic angle that partially enclosing the right border of the heart (Fig. 1B). Two-dimensional trans-thoracic echocardiography showed normal-sized cardiac chambers and a large echo-free space behind the right atrium (Fig. 2A, Video 1, 2. See corresponding video/movie images at www.anakarder.com). Contrast-enhanced thoracic computed tomography revealed a large fluid attenuation mass adherent to right atrium measuring 59x38x38 mm consistent with pericardial cyst (Fig. 2B). The diagnosis of a pericardial cyst was confirmed at surgery as well as pathologically. Postoperatively, the patient was in sinus rhythm again. During 2- month follow-up period, she was asymptomatic. Pericardial cysts are rarely seen benign congenital anomalies, which occur because of incomplete fusion of fetal mesenchymal lacunae forming the pericardium. For asymptomatic patients, conservative management with close follow-up periods is recommended. Surgical resection is recommended for treating related complications or symptoms.

Video 1. Apical 4-chamber view of echo-free space behind the right atrium

Video 2. Subcostal view revealing the echo-free space adjacent to right atrium

Uğur Canpolat, Kudret Aytemir

Department of Cardiology, Faculty of Medicine, Hacettepe University, Ankara-Turkey

Address for Correspondence/Yazışma Adresi: Dr. Uğur Canpolat
Hacettepe Üniversitesi Tıp Fakültesi, Kardiyoloji Anabilim Dalı, Ankara-Türkiye
Phone: +90 312 305 17 80 Fax: +90 312 305 41 37
E-mail: dru_canpolat@yahoo.com

Available Online Date/Çevrimiçi Yayın Tarihi: 13.04.2012

©Telif Hakkı 2012 AVES Yayıncılık Ltd. Şti. - Makale metnine www.anakarder.com web sayfasından ulaşılabilir.

©Copyright 2012 by AVES Yayıncılık Ltd. - Available on-line at www.anakarder.com
doi:10.5152/akd.2012.115

Transected common hepatic artery and treatment

Tranekte ana hepatik arter ve tedavisi

A 17-year-old trauma patient had an acute drop in blood pressure on the computed tomography scanner. The vessel cutoff sign is depicted at the origin of the common hepatic artery (CHA) on the coronal MIP reconstructed computed tomography angiography (Fig. 1). Differential includes dissection, avulsion, and embolus. He went immediately to exploratory laparotomy-the source was not identified, and all quadrants were packed.

Emergent aortogram revealed brisk extravasations from the CHA origin (Fig. 2). The CHA was selected, and the guide wire passed into an extra vascular space. A 8mm Amplatzter Vascular Plug II (St. Jude Medical, St. Paul, MN) was positioned in the CHA as well as celiac artery origin (Fig. 3). Post embolization aortogram shows cessation of the bleeding (Fig. 4). His volume and pressor requirements dropped almost

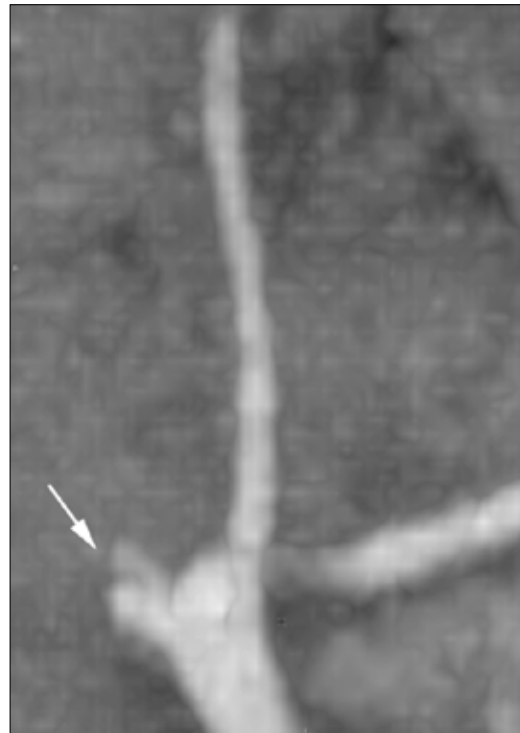

Figure 1. Coronal MIP reconstructed image shows the vessel cutoff sign (arrow) at the origin of the common hepatic artery

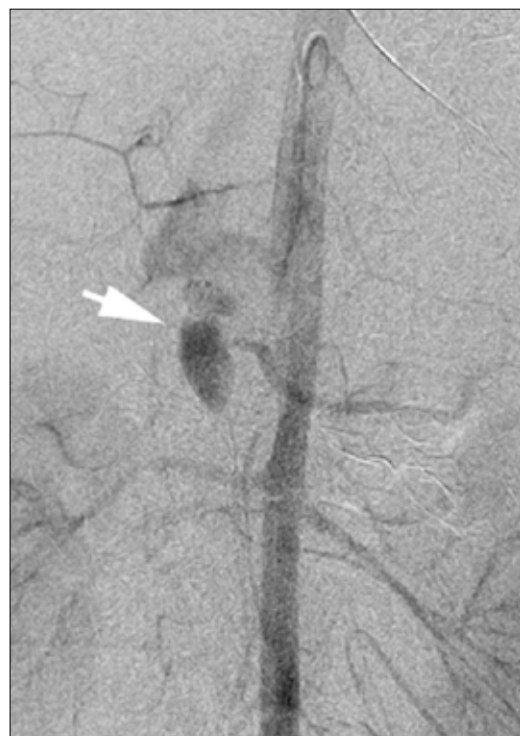

Figure 2. Emergent aortogram revealed brisk extravasation (arrow) from the common hepatic artery origin