

Chest X-ray in a hypertensive patient with stage 2 diastolic dysfunction

Evre 2 diyastolik disfonksiyonu bulunan hipertansif bir hastada akciğer grafisi

A 46-year-old woman presented with exertional dyspnea and leg swelling for 2 months. Her past medical history includes familial hyperlipidemia and uncontrolled hypertension for 6 years. She was evaluated for these complaints in another center. There was an opacity with regular contours at right lung middle lobe on her chest X-ray (Fig. 1). Electrocardiography revealed normal sinus rhythm with no abnormal changes. Transthoracic echocardiography showed left ventricular ejection fraction of 61%, left ventricular hypertrophy, mild mitral regurgitation, stage II left ventricular diastolic dysfunction and ratio of transmitral to septal myocardial flow velocities during early filling (septal E/e') equal to 10. Biochemical tests were within normal reference limits except brain natriuretic peptide (BNP) level of 215 pg/mL (N: 0-100 pg/mL). Therefore, thoracic computerized tomography (CT) was performed for differential

diagnosis: There was a localized fluid collection in right major fissure with 20x22x32 mm diameters (Fig. 2), and reported as phantom tumor. Due to these findings, peroral diuretic treatment was initiated in that medical centre. After 2 weeks, control chest X-ray was performed (Fig. 3). So, the patient was admitted to our hospital with the same complaints. The physical examination was unremarkable. Her chest X-rays and thorax CT were evaluated again; no change in size of the mass was observed. Although its location is relevant for phantom tumor, there are no clinical symptoms and findings of heart failure. Fissural cyst hydatid was thought in differential diagnosis, but the test for ecchinococcus IHA was negative. Abdominal ultrasonography was performed and there was no cystic lesion in liver.

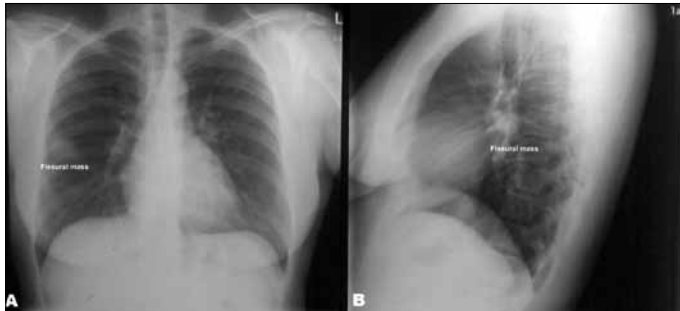


Figure 1. Posteroanterior chest-X-ray showing round-shaped opacity located at right major fissure

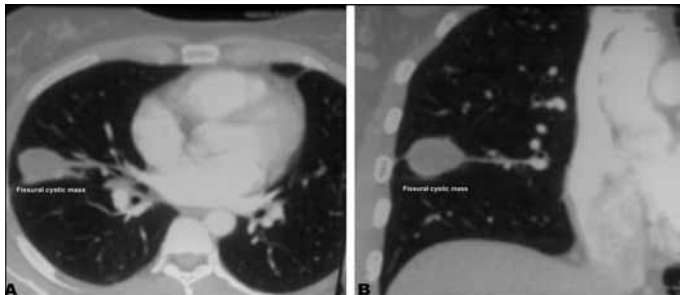


Figure 2. The thoracic CT appearance of a fissural cyst (A). Cystic lesion was located at right major fissure (B).

CT - computerized tomography

What is your diagnosis?

1. Diastolic dysfunction
2. Tumor
3. Hydatid cyst
4. Local pleural liquid or empyema

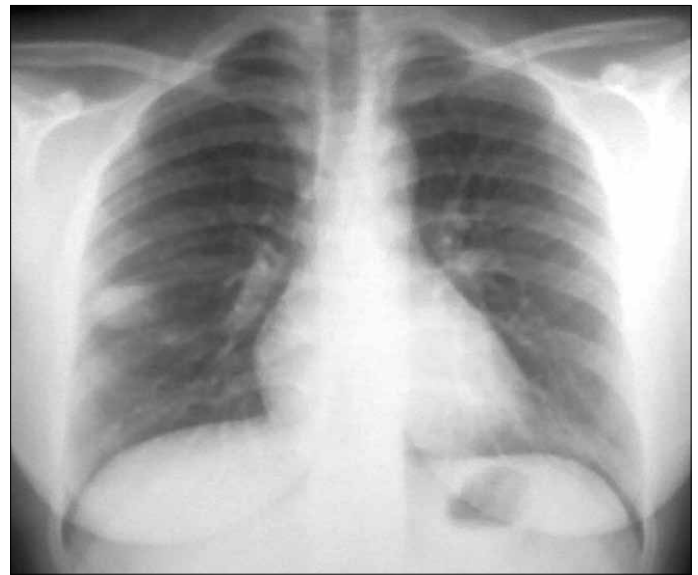

Figure 3. Control chest X-ray

Answer: p. 455

Address for Correspondence/Yazışma Adresi: Dr. Uğur Canpolat, Hacettepe Üniversitesi Tıp Fakültesi, Kardiyoloji Anabilim Dalı
06100, Sıhhiye, Ankara-*Türkiye* Phone: +90 312 305 17 80 Fax: +90 312 305 41 37 E-mail: dru_canpolat@yahoo.com

Available Online Date/Çevrimiçi Yayın Tarihi: 23.05.2012

© Telif Hakkı 2012 AVES Yayıncılık Ltd. Şti. - Makale metnine www.anakarder.com web sayfasından ulaşılabilir.

© Copyright 2012 by AVES Yayıncılık Ltd. - Available on-line at www.anakarder.com

doi:10.5152/akd.2012.148