

## CARTO Three-Dimensional Non-Fluoroscopic Electroanatomic Mapping for Catheter Ablation of Arrhythmias: A Useful Tool or an Expensive Toy for the Electrophysiologist?

Firat Duru, MD.

Arrhythmia and Electrophysiology, Division of Cardiology, Cardiovascular Center, University Hospital of Zurich

---

**Abstract:** This review enlightens the application issues of the novel CARTO electroanatomic mapping system (Biosense Webster, Diamond Bar, CA, USA) in both research and clinical electrophysiology.

It is a very useful tool in catheter ablation procedures in patients with sustained atrial tachycardias, macroreentrant atrial arrhythmias after surgical correction of congenital heart disease, and ventricular tachycardia in the setting of previous myocardial infarction or other structural heart disease. It can also be useful in other types of arrhythmias, including isthmus dependent atrial flutter and idiopathic ventricular tachycardia, by guiding the ablation procedure and limiting fluoroscopy. The major drawbacks for more widespread use of electroanatomic mapping at present time include the inability to map nonsustained arrhythmias and the associated high costs of the mapping system. (*Anadolu Kardiyol Derg, 2002; 4: 330-7*)

**Key Words:** Arrhythmia, electroanatomic mapping, ablation

---

### Introduction

Radiofrequency catheter ablation has evolved to be the therapy of choice in patients with a broad spectrum of cardiac tachyarrhythmias. The most important prerequisite for successful catheter ablation is exact mapping of focal and reentrant arrhythmias and identification of target sites during the electrophysiologic study. Conventional mapping traditionally relies on fluoroscopy, which has obvious limitations, such as marked x-ray exposure during prolonged procedures. There are other shortcomings of conventional fluoroscopic mapping, such as low spatial resolution and the inability to navigate to a pre-defined site.

Recently, several mapping systems have been introduced to facilitate catheter ablation procedures. The CARTO electroanatomic mapping system (Biosense Webster, Diamond Bar, CA, USA) is currently

the most commonly used system and provides a novel endocardial mapping method that enables the generation of three-dimensional color-coded maps of impulse propagation within the cardiac chambers. Using electromagnetic technology, the CARTO system has the ability to combine electrophysiological and spatial information, and therefore, it provides a unique tool for both research and clinical electrophysiology.

### Electroanatomic Mapping System: Basic Concepts

The CARTO electroanatomic mapping system enables accurate determination of location and orientation of the catheter and simultaneously records the intracardiac local electrogram from the catheter tip. This method was first introduced for clinical use in 1996 (1). The components of the system are shown in Figure 1. Both mapping and ablation is performed using a special steerable catheter, which has a tiny location sensor embedded in the catheter tip consisting of three miniaturized coils that is tracked by the CARTO system (Figure 2). A positional reference patch is placed on the patient's back and

---

Address for Correspondence: Firat Duru, M.D.,  
Arrhythmia and Electrophysiology, Division of Cardiology,  
Cardiovascular Center, University Hospital of Zurich  
Rämistr. 100, CH-8091, Zurich, Switzerland  
Phone: 41 1 2552565 Fax: 41 1 2554597  
e-mail: firat.duru@dim.usz.ch

enables correction for patient motion and movement of the heart within the patient (e.g. respiration). A location pad attached to the bottom of the patient table generates three ultra-low magnetic fields and tracks the tip of the ablation catheter, and its position is displayed real time via an icon on the computer screen. The mapping catheter and reference patch are plugged into the junction box and signals are sent over to the standard electrophysiology recording system. Information from the location pad and ECG signals are sent to a data acquisition and display system that analyzes the signals, determines location of the catheter tip, and generates maps using the gathered anatomical and electrophysiological data. The accuracy of the system was tested in both in vitro and in vivo studies and was found to be highly reproducible and accurate (2,3).

By dragging the mapping catheter over the endocardial surface of a cardiac chamber, consecutive end-diastolic locations of the catheter tip are collected. Using these location points, the three-dimensional geometry of the chamber is reconstructed in real time along with the electrophysiological information, which is superimposed on the electroanatomical map. The CARTO system generates different types of maps to facilitate a three-dimensional understanding of the electrical activation wavefront for precise and quick identification focal onsets or reentrant circuits: In activation map, the local activation time is color-coded and superimposed on the anatomical map. The earliest activation sites are colored red, and the latest activation sites are color-coded purple (Figure 3). The propagation map lets the electrophysiologist view cine like version of the electrical propa-

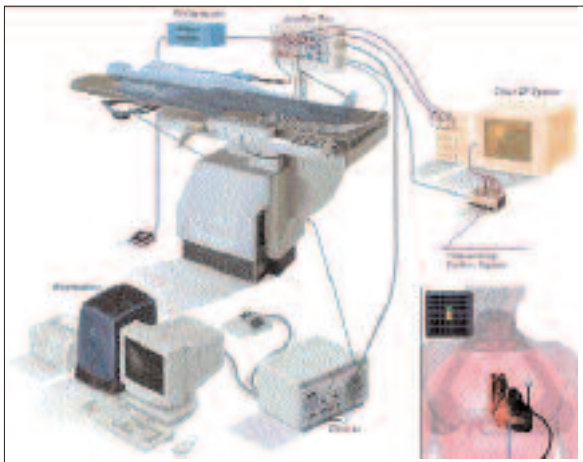


Figure 1: Typical setup of the CARTO electroanatomical mapping system in the electrophysiology laboratory.

gation of the heart. Propagation maps can also assist in the validation of end points in the procedure to confirm line of block and pinpoint localization of any gaps in the line. The voltage map is color-coded red for the lowest voltages and purple for the largest voltages, and identifies areas of healthy and diseased myocardium (e.g. scar tissue). The mesh map displays the reconstruction based on the actually sampled location points during the procedure and is used for viewing through the chamber or determining exact anatomical relationships. Each of these maps can be rotated to best visualize anatomy and closely examine its electrophysiology. In addition to the reconstruction of the three-dimensional maps, key anatomical landmarks, such as the tricuspid annulus, superior and inferior vena cava, can be precisely defined using the system.

### Clinical Applications of Electroanatomical Mapping

**Atrial Tachycardias:** The CARTO electroanatomic mapping technology facilitates catheter ablation of ectopic atrial tachycardia by providing a precise anatomic reconstruction of the atria. In most cases with sustained or frequently recurrent atrial tachycardias, successful results are obtained usually with a small number of radiofrequency applications at the earliest endocardial activation site (Figure 3) (4-7).

Intraatrial macroreentrant tachycardias frequ-




Figure 2: A tiny location sensor is embedded in the catheter tip consisting of three miniaturized coils that is tracked by the CARTO system. The locator pad placed beneath the patient table generates 3 ultra-low magnetic fields to identify the location and orientation of the sensor.

ently complicate the clinical course in patients with congenital heart disease who have undergone palliative surgical interventions (e.g. Senning and Mustard procedures) leading to significant morbidity and even mortality. Multiple isolated channels between scars and anatomical barriers are responsible for these macroreentries. Ablative therapy with radiofrequency energy offers a potential for cure for these patients but the conventional approach using multi-electrode recordings and fluoroscopic guidance is technically difficult and provides limited success. Three-dimensional mapping allows visualization of the activation wavefronts along anatomical and surgically created barriers and has shown promising results in guiding ablative therapy (8-11).

**Atrial flutter:** Typical human atrial flutter arises from a well-defined macroreentrant circuit utilizing the subeustachian isthmus between the tricuspid annulus and the ostium of the inferior vena cava as its critical zone of slow conduction. Creation of a complete line of conduction block across the flutter isthmus eliminates the arrhythmia. The success rate in isthmus dependent atrial flutter (typical counter clockwise or clockwise) has approached 90 to 95%, given the stable target anatomical locations and electrogram characteristics. Therefore, CARTO map-

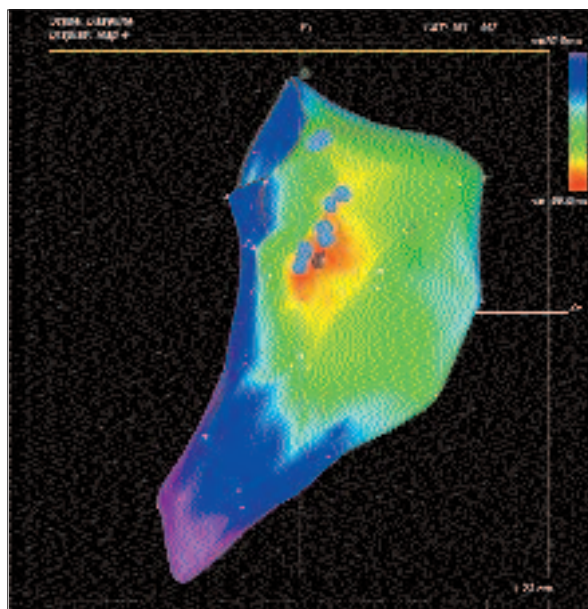


Figure 3: Activation map displaying an ectopic atrial tachycardia arising from the superior aspect of crista terminalis. Color bar indicates the local activation time relative to the reference catheter. Red tag indicates the site where a single radiofrequency application terminated the tachycardia rendering it non-inducible.

ping can be expected to provide only minor benefit in the overall success rate. However, the system allows precise localization of the anatomical boundaries of the reentrant circuit (Figure 4) and facilitates ablation by guiding linear lesion creation and may help to reduce the fluoroscopy exposure (12-14). It provides unique views that cannot be obtained by conventional fluoroscopy, such as the bottom view, which fully exposes the flutter isthmus and facilitates rapid ablation procedures by using minimal approaches. The CARTO system may also be particularly useful in identifying the gaps in the ablation line using activation or propagation maps in the setting of recurrent flutter after previous ablation, to guide repeat ablation (15). Similarly, in patients with atypical left atrial flutters, the reentry circuit with a protected isthmus can be identified in most patients by electroanatomic mapping (16).

**Ventricular Tachycardia:** Electroanatomic mapping is helpful in identifying sites for catheter ablation in highly symptomatic patients with refractory VT

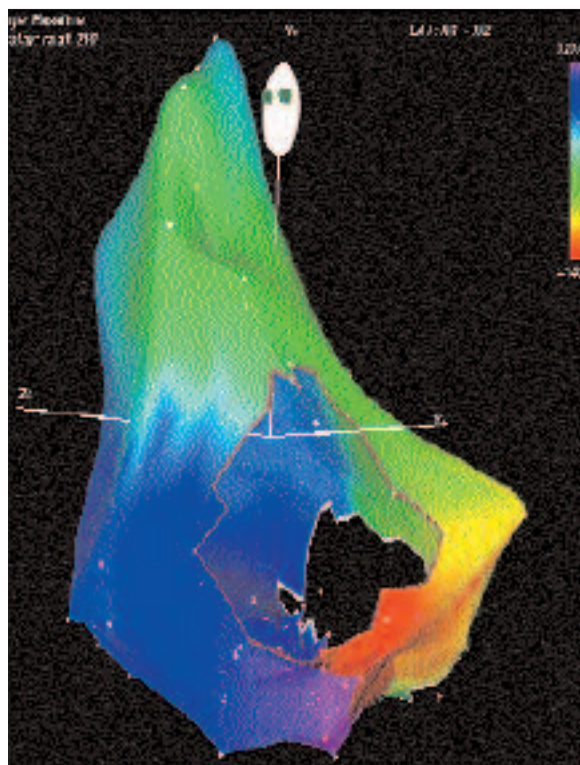


Figure 4: Left anterior oblique view of common atrial flutter displaying counter clockwise activation around the tricuspid annulus. Note that the earliest and the latest activated areas meet each other; the so-called "head meets tail" pattern, a typical feature of macro-reentrant arrhythmias.

associated with myocardial scarring. (e.g. patients with an implantable cardioverter defibrillator with multiple shocks) (17,18). In the presence of a sustained ventricular tachycardia, activation maps can be acquired to define the circuit. However, since most arrhythmias are nonsustained, or associated with multiple reentry circuits or hemodynamic instability, the ablation procedure can be quite challenging. In these situations, local bipolar voltage maps have been successfully used to identify the complex substrate responsible for ventricular tachycardia. Linear endocardial lesions extending from the dense scar to the normal myocardium or anatomic boundary seem to be effective in controlling unmappable arrhythmias. Electroanatomic mapping can also be very useful in the setting of ventricular tachycardia that occurs after surgical correction of congenital heart disease (e.g. tetralogy of Fallot) (19).

**Atrial Fibrillation:** Electroanatomic mapping can guide percutaneous linear lesion creation mimicking the surgical maze procedure in an attempt to compartmentalize the atria into small sections, which cannot support wavefront reentry. However, this can be a time consuming process and completeness of linear lesions is difficult to assure. Linear lesions performed in the left atrium using percutaneous cat-

heter approaches or by surgical means are often pro-arrhythmic leading to incisional flutters. Electroanatomic mapping may be useful in identification of the remaining gaps and ablation of residual flutters (Figure 5) (20).

Circumferential radiofrequency ablation of pulmonary vein ostia under electroanatomic mapping guidance has been introduced as a new anatomic approach for curing atrial fibrillation (21). The utility of this technique needs to be confirmed in larger patient populations but this approach possibly holds greater promise for the future.

**Patient Selection in Other Arrhythmias:** Conventional catheter ablation under fluoroscopy guidance has a very high success in the treatment of AV-nodal reentrant tachycardia and accessory pathways. Therefore, there is no need for novel mapping techniques in the management of these arrhythmias. However, electroanatomic mapping may improve the safety of mapping and ablation procedures by allowing localization of critical cardiac structures such as the atrioventricular node and His bundle. Therefore, in selected cases (e.g. residual arrhythmias after previous conventional ablation attempts), it may be used to create accurate maps of the Koch's triangle and valvular annulus, and to guide application of ra-

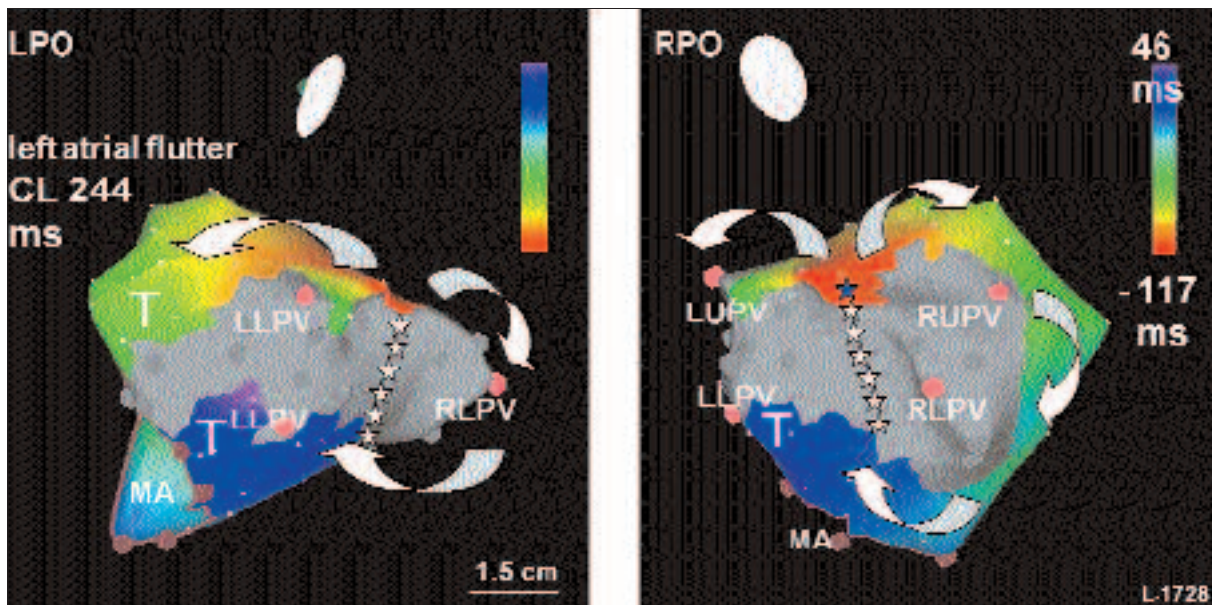


Figure 5: Electroanatomic maps recorded during the tachycardia in the left posterior oblique (LPO) and right posterior oblique (RPO) views in a patient who previously underwent linear ablation for atrial fibrillation in the left atrium. Gray color represents the scar caused by ablation lesions. The arrhythmia reveals a "figure-of-nine" mechanism. The blue star shows the exit site where a single radiofrequency energy application terminated the flutter circuit and rendered it non-inducible LLPV: lower pulmonary vein; LUPV: left upper pulmonary vein; MA: mitral annulus; RLPV: right lower pulmonary vein; RUPV: right upper pulmonary vein. (Reproduced from reference (20) with permission from the publisher).

diofrequency energy (22,23). Likewise, electroanatomical mapping seems to facilitate and improve the ablation results of inappropriate sinus tachycardia (24). For the same reasons, the system may be used in patients with idiopathic ventricular tachycardia (e.g. right ventricular outflow tract tachycardia and fascicular ventricular tachycardia) (25).

**Novel Applications of Electroanatomic Mapping:** Electromagnetic voltage mapping can be used in selected patients with structural heart disease to determine the optimal site for permanent pacemaker lead placement. For example, it may be utilized as a guide for successful implantation of an atrial lead in patients with Ebstein's anomaly associated with a severely dilated right atrium and extremely low-amplitude voltage signals (26).

Electroanatomic mapping can also be used to identify the dysplastic regions in patients with arrhythmogenic right ventricular dysplasia (27). The ability to accurately identify the presence, location and extent of the pathologic substrate may have important diagnostic, prognostic and therapeutic implications (Figure 6).

The CARTO system has also been used in basic science applications. For example, monophasic action potentials recordings using electroanatomic mapping can be utilized to evaluate the global sequence of repolarization over the ventricular endocardium (28).

### Current Limitations and Future Perspectives

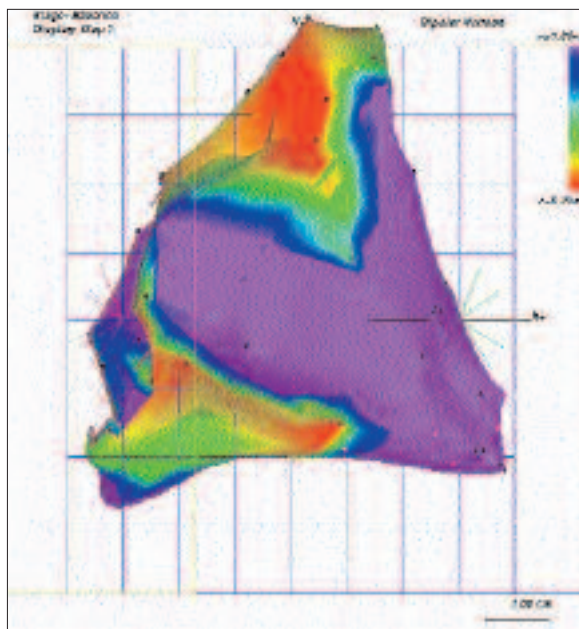
Because the CARTO system provides contact-based sequential acquisition of endocardial signals, construction of three-dimensional electroanatomical maps can be time consuming. However, this factor is operator dependent, and in experienced hands, detailed maps of a cardiac chamber can be obtained within 30 minutes. If the arrhythmia that is being mapped is not sustained or has varying cycle lengths, or in the setting of arrhythmias that are hemodynamically not well tolerated, sequential mapping is not possible. Instability of the catheter used for timing intracardiac activation and major patient movements during relative to the location pad may render the entire map inaccurate for subsequent use, requiring the construction of a whole new map. The recently introduced CARTO XP system that operates on a new platform intends to facilitate mapping of less sustained arrhythmias, and therefore, may solve so-

me of the drawbacks of the current technology.

For established indications, the major limitation for broader use of electroanatomical mapping in catheter ablation procedures at the present time is the associated cost of the CARTO system. This is further confounded by the high cost of the mapping catheter. Sterilization and reuse of the mapping catheters is possible but these catheters must be reused within 24 hours. In Europe and North America, mapping systems are increasingly used in most high volume electrophysiology laboratories. However, there is still limited availability of these systems in developing countries. It is reasonable to suggest that a sophisticated mapping technique is not an absolute requirement in every electrophysiology laboratory. However, the true benefits of novel mapping techniques for guiding catheter ablation cannot be underestimated, especially in tertiary clinics with a high number of complex arrhythmia referrals.

### Alternative Mapping Techniques for Catheter Ablation

There are currently several other mapping techniques for catheter ablation that are available for commercial use, including the EnSite noncontact map-



**Figure 6: Bipolar voltage mapping using the CARTO system demonstrates low voltage areas in the right ventricular outflow tract and the subtricuspid region (two of the three classical locations in arrhythmogenic right ventricular dysplasia).**

ping, multielectrode basket catheter, Localisa, and the Cardiac Pathways tracking system. Each of these systems has its own advantages, as well as its own limitations:

**Basket Mapping System:** The multielectrode basket catheter has a collapsible, basket shaped distal end that has 64 electrodes capable of simultaneously recording electrograms from a cardiac chamber. The mapping system allows fast reconstruction of color-coded endocardial activation maps, and therefore, may facilitate mapping of hemodynamically unstable tachycardias (29). However, the basket catheter has demonstrated only limited clinical utility because of its poor spatial resolution.

**Non-Contact Mapping System (EnSite):** The EnSite system utilizes a 9 Fr multi-electrode array catheter with 64 electrodes mounted on 7.5 ml balloon to record intracavitary far-field potentials using a mathematical equation (inverse Laplace). The system permits simultaneous multi-site intracardiac mapping and has the capability to localize any conventional roving electrode catheter. The system has the advantage of providing high resolution maps of the entire cardiac chamber from a single tachycardia beat, and therefore, is preferred in patients with transient or multiple arrhythmias (30-32). The limitations of the system include the large catheter size, deterioration of virtual electrogram quality in large chambers, inadequate substrate mapping, and the associated costs.

**Localisa Mapping System:** The Localisa system is a real time three-dimensional catheter localization technique, which uses externally applied electrical fields in 3 orthogonal directions with slightly different frequencies. A standard intracardiac catheter records the voltage drop across the internal organs (in each direction) and the system then derives the three-dimensional position of the catheter tip. There is only limited clinical experience (33-35) using this system so far and there are concerns regarding the accuracy of catheter localization. However, the simple principle of the system and its compatibility with any catheter makes it attractive in terms of low costs and ease of operation.

**Cardiac Pathways Tracking System:** This system uses the principle of ultrasound ranging to calculate the distance between the transmitting transducer and the receiving transducer. Two multi-transducer catheters are positioned in stable locations in right ventricular apex and coronary sinus and these catheters track the location of a third catheter. The

system has the advantage of displaying the three-dimensional anatomy and electrical recordings on the same platform but it uses only special catheters and the system has not been validated in humans yet (36).

## Summary

The CARTO non-fluoroscopic electroanatomic mapping system identifies accurate real-time display of the catheter location and orientation and provides three-dimensional maps, such as activation, propagation, and voltage maps, with the electrophysiological information color-coded and superimposed on the anatomy. Additionally, the system enables catheter navigation to target areas to further facilitate radiofrequency ablation procedures. It is a very useful tool in catheter ablation procedures in patients with sustained atrial tachycardias, macroreentrant atrial arrhythmias after surgical correction of congenital heart disease, and ventricular tachycardia in the setting of previous myocardial infarction or other structural heart disease. It can also be useful in other types of arrhythmias, including isthmus dependent atrial flutter and idiopathic ventricular tachycardia, by guiding the ablation procedure and limiting fluoroscopy. The major drawbacks for more widespread use of electroanatomic mapping at present time include the inability to map nonsustained arrhythmias and the associated high costs of the mapping system. Despite some limitations, however, CARTO and other sophisticated mapping systems have added insight into mechanisms of arrhythmogenesis and continue to revolutionize the treatment of complex arrhythmias.

## References

1. Ben-Haim SA, Osadchy D, Schuster I, Gepstein L, Hayam G, Josephson ME. Nonfluoroscopic, in vivo navigation and mapping technology. *Nat Med* 1996; 2: 1393-5.
2. Gepstein L, Hayam G, Ben-Haim SA. A novel method for nonfluoroscopic catheter-based electroanatomical mapping of the heart. In vitro and in vivo accuracy results. *Circulation* 1997; 95: 1611-22.
3. Gepstein L, Evans SJ. Electroanatomical mapping of the heart: basic concepts and implications for the treatment of cardiac arrhythmias. *Pacing Clin Electrophysiol* 1998; 21: 1268-78.
4. Kottkamp H, Hindricks G, Breithardt G, Borggrefe M. Three-dimensional electromagnetic catheter techno-

- logy: electroanatomical mapping of the right atrium and ablation of ectopic atrial tachycardia. *J Cardiovasc Electrophysiol* 1997; 8: 1332-7.
5. Marchlinski F, Callans D, Gottlieb C, Rodriguez E, Coyne R, Kleinman D. Magnetic electroanatomical mapping for ablation of focal atrial tachycardias. *Pacing Clin Electrophysiol* 1998; 21: 1621-35.
  6. Weiss C, Willems S, Rueppel R, Hoffmann M, Meinertz T. Electroanatomical Mapping (CARTO) of ectopic atrial tachycardia: impact of bipolar and unipolar local electrogram annotation for localization the focal origin. *J Interv Card Electrophysiol* 2001; 5: 101-7.
  7. Hoffmann E, Reithmann C, Nimmermann P, et al. Clinical experience with electroanatomic mapping of ectopic atrial tachycardia. *Pacing Clin Electrophysiol* 2002; 25: 49-56.
  8. Dorostkar PC, Cheng J, Scheinman MM. Electroanatomical mapping and ablation of the substrate supporting intraatrial reentrant tachycardia after palliation for complex congenital heart disease. *Pacing Clin Electrophysiol* 1998; 21: 1810-9.
  9. Reithmann C, Hoffmann E, Dorwarth U, Remp T, Steinbeck G. Electroanatomical mapping for visualization of atrial activation in patients with incisional atrial tachycardias. *Eur Heart J* 2001; 22: 237-46.
  10. Love BA, Collins KK, Walsh EP, Triedman JK. Electroanatomic characterization of conduction barriers in sinus/atrially paced rhythm and association with intraatrial reentrant tachycardia circuits following congenital heart disease surgery. *J Cardiovasc Electrophysiol* 2001; 12: 17-25.
  11. Delacretaz E, Ganz LI, Soejima K, et al. Multi atrial macroreentry circuits in adults with repaired congenital heart disease: entrainment mapping combined with three-dimensional electroanatomic mapping. *J Am Coll Cardiol* 2001; 37: 1665-76.
  12. Nakagawa H, Jackman WM. Use of a three-dimensional, nonfluoroscopic mapping system for catheter ablation of typical atrial flutter. *Pacing Clin Electrophysiol* 1998; 21: 1279-86.
  13. Kottkamp H, Hugl B, Krauss B, et al. Electromagnetic versus fluoroscopic mapping of the inferior isthmus for ablation of typical atrial flutter: A prospective randomized study. *Circulation* 2000; 102: 2082-6.
  14. Willems S, Weiss C, Ventura R, et al. Catheter ablation of atrial flutter guided by electroanatomic mapping (CARTO): a randomized comparison to the conventional approach. *J Cardiovasc Electrophysiol* 2000; 11: 1223-30.
  15. Sra J, Bhatia A, Dhala A, et al. Electroanatomic mapping to identify breakthrough sites in recurrent typical human flutter. *Pacing Clin Electrophysiol* 2000; 23: 1479-92.
  16. Ouyang F, Ernst S, Vogtmann T, et al. Characterization of reentrant circuits in left atrial macroreentrant tachycardia: critical isthmus block can prevent atrial tachycardia recurrence. *Circulation* 2002; 105: 1934-42.
  17. Sra J, Bhatia A, Dhala A, et al. Electroanatomically guided catheter ablation of ventricular tachycardias causing multiple defibrillator shocks. *Pacing Clin Electrophysiol* 2001; 24: 1645-52.
  18. Marchlinski FE, Callans DJ, Gottlieb CD, Zado E. Linear ablation lesions for control of unmappable ventricular tachycardia in patients with ischemic and nonischemic cardiomyopathy. *Circulation* 2000; 101: 1288-96.
  19. Stevenson WG, Delacretaz E, Friedman PL, Ellison KE. Identification and ablation of macroreentrant ventricular tachycardia with the CARTO electroanatomical mapping system. *Pacing Clin Electrophysiol* 1998; 21: 1448-56.
  20. Duru F, Hindricks G, Kottkamp H. Atypical left atrial flutter after intraoperative radiofrequency ablation of chronic atrial fibrillation: successful ablation using three-dimensional electroanatomic mapping. *J Cardiovasc Electrophysiol* 2001; 12: 602-5.
  21. Pappone C, Rosanio S, Oreto G, et al. Circumferential radiofrequency ablation of pulmonary vein ostia: A new anatomic approach for curing atrial fibrillation. *Circulation* 2000; 102: 2619-28.
  22. Cooke PA, Wilber DJ. Radiofrequency catheter ablation of atrioventricular nodal reentry tachycardia utilizing nonfluoroscopic electroanatomical mapping. *Pacing Clin Electrophysiol* 1998; 21: 1802-9.
  23. Worley SJ. Use of a real-time three-dimensional magnetic navigation system for radiofrequency ablation of accessory pathways. *Pacing Clin Electrophysiol* 1998; 21: 1636-45.
  24. Marrouche NF, Beheiry S, Tomassoni G, et al. Three-dimensional nonfluoroscopic mapping and ablation of inappropriate sinus tachycardia. Procedural strategies and long-term outcome. *J Am Coll Cardiol* 2002; 39: 1046-54.
  25. Nademanee K, Kosar EM. A nonfluoroscopic catheter-based mapping technique to ablate focal ventricular tachycardia. *Pacing Clin Electrophysiol* 1998; 21: 1442-7.
  26. Kloosterman EM, Yamamura K, Alba J, Mitrani RD, Myerburg RJ, Interian A Jr. An innovative application of anatomic electromagnetic voltage mapping in a patient with Ebstein's anomaly undergoing permanent pacemaker implantation. *J Cardiovasc Electrophysiol* 2000; 11: 99-101.
  27. Boulos M, Lashevsky I, Reisner S, Gepstein L. Electroanatomic mapping of arrhythmogenic right ventricular dysplasia. *J Am Coll Cardiol* 2001; 38: 2020-7.
  28. Yuan S, Kongstad O, Hertervig E, Holm M, Grins E, Olsson B. Global repolarization sequence of the ventricular endocardium: monophasic action potential mapping in swine and humans. *Pacing Clin Electrophysiol* 2001; 24: 1479-88.

29. Schalij MJ, van Ruyge FP, Siezena M, van der Velde ET. Endocardial activation mapping of ventricular tachycardia in patients: first application of a 32-site bipolar mapping electrode catheter. *Circulation* 1998; 98: 2168-79.
30. Schilling RJ, Peters NS, Davies DW. Simultaneous endocardial mapping in the human left ventricle using a noncontact catheter: comparison of contact and reconstructed electrograms during sinus rhythm. *Circulation* 1998; 98: 887-98.
31. Gornick CC, Adler SW, Pederson B, Hauck J, Budd J, Schweitzer J. Validation of a new noncontact catheter system for electroanatomic mapping of left ventricular endocardium. *Circulation* 1999; 99: 829-35.
32. Strickberger SA, Knight BP, Michaud GF, Pelosi F, Morady F. Mapping and ablation of ventricular tachycardia guided by virtual electrograms using a noncontact, computerized mapping system. *J Am Coll Cardiol* 2000; 35: 414-21.
33. Wittkampfh FH, Wever EF, Derksen R, et al. Localisa: new technique for real-time 3-dimensional localization of regular intracardiac electrodes. *Circulation* 1999; 99: 1312-7.
34. Wittkampfh FH, Wever EF, Vos K, et al. Reduction of radiation exposure in the cardiac electrophysiology laboratory. *Pacing Clin Electrophysiol* 2000; 23: 1638-44.
35. Molenschot M, Ramanna H, Hoorntje T, et al. Catheter ablation of incisional atrial tachycardia using a novel mapping system: Localisa. *Pacing Clin Electrophysiol* 2001; 24: 1616-22.
36. Dixit S, Callans DJ. Role of contact and noncontact mapping in the curative ablation of tachyarrhythmias. *Curr Opin Cardiol* 2002; 17: 65-72.



OGÜ Eskişehir

Prof.Dr.Arif Akşit