

# Annular insertion levels of atrioventricular valves along the interventricular septum alone can lead to misdiagnosis of ventricular morphology

*Atriyovenriküler kapakların interventriküler septuma annuler yapışma seviyesi ventrikül morfolojisini belirlemede yanıltıcı olabilir*

*Funda Öztunç, Ayşe Güler Eroglu, Tevfik Demir*

Division of Pediatric Cardiology, Department of Pediatrics, Cerrahpaşa Medical Faculty Istanbul University, İstanbul, Turkey

## Introduction

It is known that, normally the tricuspid annulus has a lower insertion site along the interventricular septum, as distinct from the mitral annulus (1-5).

Ebstein malformation is an abnormal location of some part of the annular attachment of the leaflets of the tricuspid valve away from the atrioventricular junction. In corrected transposition patients with normal atrial arrangement left-sided (tricuspid) atrioventricular valve annulus has lower insertion with atrioventricular discordance with or without displacement of the septal or posterior leaflets. Rarely Ebstein's malformation can affect the morphologically mitral valve (6-7).

As opposite to these, we reported a case with concordant atrioventricular and discordant ventriculoarterial connections, ventricular septal defect, pulmonary subvalvular stenosis and patent ductus arteriosus in whom the septal insertion site of the tricuspid annulus was higher than the septal insertion site of the mitral annulus.

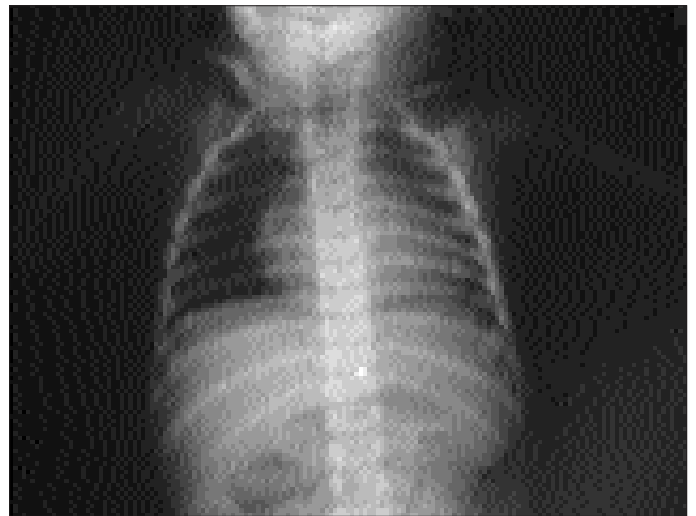## Case report

A one-year-old boy was referred for surgical treatment of ventricular septal defect and pulmonary stenosis. The patient was born after a normal pregnancy, labor and delivery and weighed 2000 gr. He was evaluated for cyanosis at another center and diagnosis of ventricular septal defect and pulmonary stenosis was made. He had hypercyanotic spells. His growth and development had been retarded. There was generalized cyanosis. The first heart sound was normal. The second sound was single and loud. There was a grade 3/6 systolic ejection murmur along the left sternal border in the second-fourth intercostal space. The remainder of the physical examination was normal.

The chest roentgenogram showed mild cardiac enlargement and decreased pulmonary vascular markings (Fig 1). The

electrocardiogram showed right axis and right ventricular hypertrophy.

At echocardiography, the cardiac apex was directed to the left. Usual atrial arrangement was found. The right-sided ventricle had coarse trabeculations (Fig 2a). The right-sided atrioventricular valve had numerous chords, which were attached directly onto the septum, but its annulus had a higher septal insertion (Fig 2b). This ventricle was defined as morphologically right ventricle. The left-sided ventricle had fine trabeculations. The left-sided atrioventricular valve did not have chordal attachment onto the septum but its annulus had a lower (6mm) septal insertion. This ventricle was defined as morphologically left ventricle. Atrioventricular connections were concordant. There was no atrioventricular valve regurgitation. The morphologically right ventricle was connected to the anterior aorta and



**Figure 1. The chest roentgenogram shows cardiac enlargement and decreased pulmonary vascular markings.**

morphologically left ventricle was connected to the posterior pulmonary artery (Fig 3). The great arteries were parallel to each other. The ventriculoarterial connections were discordant. A large muscular outlet ventricular septal defect, severe pulmonary subvalvar stenosis and patent ductus arteriosus were showed. Left modified Blalock-Taussig shunt was performed and Rastelli operation was planned.

## Discussion

The morphology of a given chamber should be determined on the basis of its most constant component. It is possible to recognize the ventricle on the basis of the structure of its apical trabecular component (1-5). The morphologically right ventricle has coarse apical trabeculations and morphologically left vent-

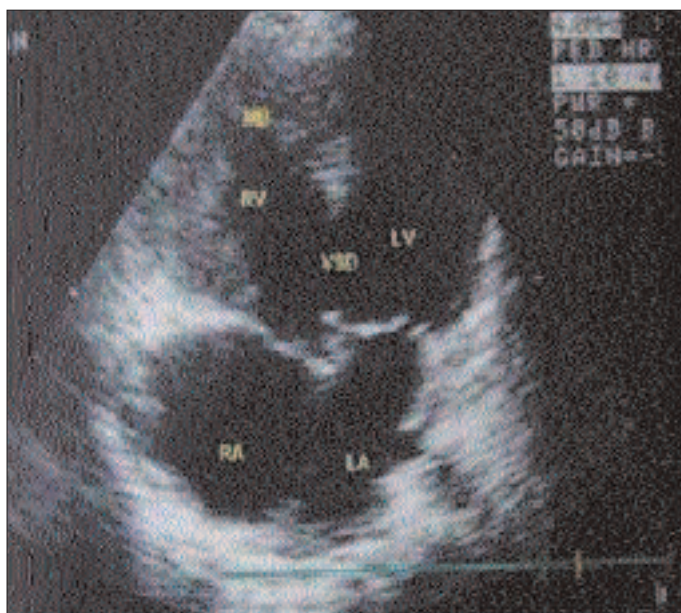
ricule has fine apical trabeculations (1-5). Because the atrioventricular valves travel with their corresponding ventricles, the identification of these valves provides an indirect but reliable clinical means of establishing ventricular morphology. The attachment of numerous chords onto the ventricular septum is a reliable distinguishing feature of the tricuspid valve (1-5). The tricuspid valve virtually always connects to a morphologically right ventricle, whereas the mitral valve connects to a morphologically left ventricle. From a practical standpoint, the tricuspid annulus has a lower septal insertion, as distinct from the mitral annulus in malformed as well as normal hearts (1-5).

In our case, right-sided morphologically right ventricle had coarse apical trabeculations and left-sided morphologically left ventricle has fine apical trabeculations. The right-sided atrioventricular valve had numerous chords, which were attached directly onto the septum but its annulus had higher septal insertion. The left-sided atrioventricular valve annulus had a lower septal insertion level. Despite higher annular insertion level along the septum, right-sided atrioventricular valve was defined as tricuspid valve because of chordal septal attachments.

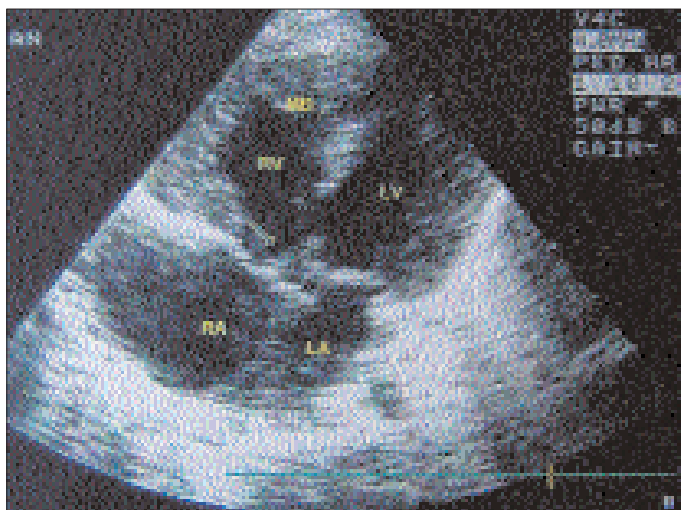
In corrected transposition patients with normal atrial arrangement left-sided (tricuspid) atrioventricular valve annulus has lower insertion with atrioventricular discordance with or without displacement of the septal or posterior leaflets but this valve has attachment of numerous chords onto the ventricular septum, although in our case there was no chordal attachment of left atrioventricular valve onto the septum. However, apical displacement of the septal insertion of mitral annulus was 6 mm, we could not diagnose it as a mitral valve Ebstein anomaly in this case, because the anatomy of mitral valve was normal and there was no left atrial enlargement, left atrioventricular valve regurgitation, dilatation of left atrioventricular junction and no atrialized chamber.

In our up- to-date search, we did not find similar case reported in the literature.

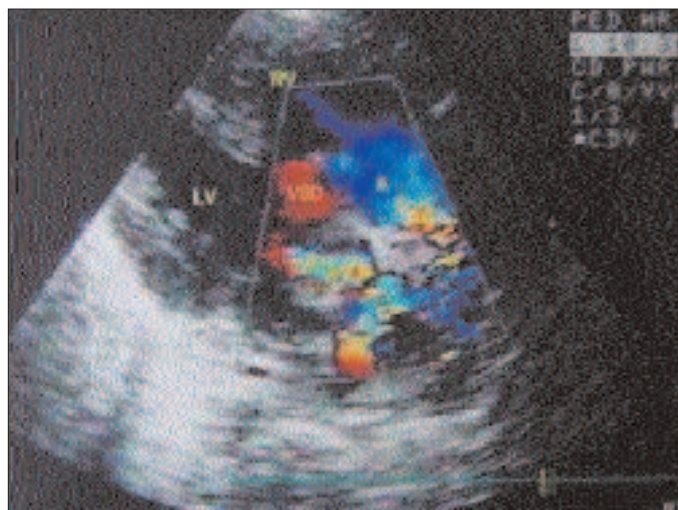
Finally, we emphasized that annular insertion levels of atrioventricular valves along the interventricular septum alone are not reliable markers of ventricular morphology. The morphology of a ventricle should be determined on the basis of its apical trabecular component.



**Figure 2a.** Apical four-chamber view shows coarse trabeculations of the right-sided morphologically right ventricle, and higher septal insertion site of the right-sided atrioventricular valve



**Figure 2b:** Arrow shows numerous chords attached directly on to the septum and atrioventricular annulus at higher septal insertion. LA: left atrium, LV: left ventricle, M: mitral valve, MB: moderator band, RA: right atrium, RV: right ventricle, VSD: ventricular septal defect



**Figure 3.** Color Doppler parasternal long- axis view shows discordant ventriculoarterial connection, large muscular outlet ventricular septal defect and subpulmonary stenosis. AO: aorta, LV: left ventricle, PA: pulmonary artery, RV: right ventricle, VSD: ventricular septal defect

## References

1. Abuhamad A. A Practical Guide to Fetal Echocardiography. 1st ed Philadelphia: Lippincott-Raven; 1997.
2. Anderson RH, Ho SY. Sequential segmental analysis -description and categorization for the millennium. *Cardiol Young* 1997; 7: 98-116.
3. Anderson RH . Anatomy. In: Anderson RH, Baker EJ, Macartney FJ, editors. *Paediatric Cardiology*. 2nd ed. London: Churchill Livingstone; 2002. p 37-55.
4. Edwards WD. Cardiac anatomy and examinations of cardiac specimens. In: Allen HD, Gutgesell HP, Clarck EB, Driscoll DJ, editors. *Heart Disease in Infants, Children, and Adolescents including the Fetus and Young Adult*. Maryland: Williams & Wilkins; 2001. p. 80-117.
5. Titus JL, Kearney DL. Cardiovascular anatomy. In: Garson A, Bricker JT, McNamara DG, editors. (eds) *The Science and Practice of Pediatric Cardiology*, Philadelphia: Lea & Febiger; 1990. p 104-134.
6. Ruschhaupt DG, Bharati S, Lev M. Mitral valve malformation of Ebstein type in absence of corrected transposition. *Am J Cardiol* 1976; 38: 109-12.
7. Jacob JL, Sobrinho SH, Lorga AM, et al. Ebstein's anomaly of the mitral valve. A very unusual congenital malformation of the heart. A case report. *Arq Bras Cardiol* 1989; 53: 283-5

### BEN SANA KÜSTÜM İZMİR - II

Bornovada ilk aşk dolu anılar  
Yüreğimde özlem, sevgi, sitem var  
Yağmur şarkı söylerdi, şiir okurdu rüzgar  
Bütün sevgilileri aldın elimden bir bir  
Ben sana küstüm İzmir...

Karşıyaka'na bir aşk eserdı imbat imbat  
Martılar dans ederdi sahilde kanat kanat  
Ömür boyu sürececek sanırdık bu saltanat  
Bütün hayallerimi aldın elimden bir bir  
Ben sana küstüm İzmir...

Bir rüya şehirdin cennet gibiydin  
Neden şimdi böyle griler giydin?  
Arkadaştın, dosttun, sevgiliydin  
Bütün rüyalarımı aldın elimden bir bir  
Ben sana küstüm İzmir...

**Dr. Yüksel Satoğlu-Gemalmaz**