

Left atrial ball-shaped thrombus mimicking myxoma detected by transthoracic echocardiography

Transtorasik ekokardiyografi ile saptanan miksoma benzeri sol atriyal top şekilli kitle

A 67-year-old woman was admitted to our clinic for elective echocardiography. She had had a history of rheumatismal valve diseases, mitral stenosis and mild aortic regurgitation known for 2 years. Four years ago she had had a stroke episode which ended with no sequels. The patient was in congestive heart failure (NYHA class II). One year ago, elective echocardiographic examination was performed in another clinic but no left atrial mass or spontaneous contrast echo were reported. Atrial fibrillation with moderate ventricular response was detected on standard 12-lead electrocardiography. Two-dimensional transthoracic echocardiography showed moderate thickening and calcification of mitral valve leaflets, narrowing of the mitral valve opening area (0.9 cm² calculated using PHT method), and mild aortic leaflet thickening, mild aortic and tricuspid regurgitations. A smooth surfaced spherical mass of 2x2 cm was seen adjacent to interatrial septum (Fig. 1). It was mobile but did not protrude through mitral valve during diastole.

Because of rheumatismal mitral stenosis and atrial fibrillation history, urgent surgical operation was performed. Intracardiac mass was resected and mitral valve was replaced with number 31 bileaflet mechanical prosthetic valve. On pathologic examination, the mass was diagnosed as an organized thrombus (Fig. 2).

Left atrial ball-shaped masses may be thrombi, vegetations or tumor. Treatment may be different in each of these entities, and includes antibiotics, anticoagulants or surgery (1). Transthoracic and transesophageal echocardiography are the procedures of choice for the diagnosis of cardiac mass involving left atrium (2). Especially, differentiation between myxoma and thrombus may be very difficult if the mass size is small, contours are smooth, or attachment size is ill-defined (3).

M. Murat Tümüklü, Erdeşir Naseri*, Köksal Ceyhan, Altay Elalmış*
From Departments of Cardiology and*Cardiovascular Surgery,
Faculty of Medicine, University of Gaziosmanpaşa, Tokat, Turkey

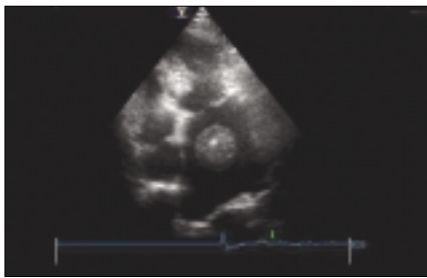


Figure 1. Site of the attachment of the left atrial mass is not clearly identified by transthoracic echocardiography

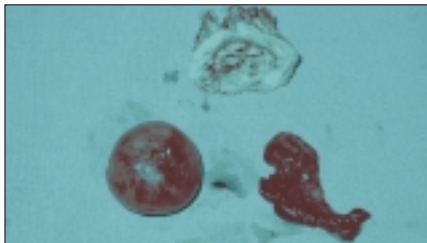


Figure 2. Left atrial ball shaped mass (2.4x2.4 cm), which was covered by a bright membrane-like formation and had elastic ball consistency, and a cedilla-like thrombus, which had no contact with the ball-like mass, were removed from left atrial appendix

References

1. Tallano JV, Gardin JM. Vegetation, tumor, mass and thrombi. In: Tallano JV, Gardin JM, editors. Textbook of Two-Dimensional Echocardiography. New York: Grune&Statton; 1993. p.239-70.
2. Alam M, Sun I. Transesophageal echocardiographic evaluation of left atrial mass lesions. J Am Soc Echocardiogr 1991; 4: 323-30.
3. Alam M. Pitfalls in the echocardiographic diagnosis of intracardiac and extracardiac masses. Echocardiogr 1993; 10: 181-91.

Address for Correspondence: Dr. Köksal Ceyhan, Gaziosmanpaşa Üniversitesi Tıp Fakültesi Kardiyoloji A.D, Tokat, Türkiye
Tel.: +90 356 212 95 00 Fax: +90 356 212 94 17 E-mail: kceyhan09@yahoo.com

Intracardiac vascularized mass

İntrakardiyak vaskülarize kitle

A 58 years old female was admitted to our outpatient clinic with atypical chest pain. She was operated 8 years ago for aortic valve replacement. Her physical examination and electrocardiographic findings were determined as normal. She was evaluated with transthoracic echocardiography. On her echocardiographic examination we notified a left atrial mass originated from interatrial septum (Fig. 1). The functions of prosthetic aortic valve were normal. Transesophageal echocardiography was performed for better interpretation of the mass. Indeed, we determined blood flow within the mass using color Doppler (Fig. 2). Although coronary arteries were normal at angiography, we showed an abnormal vascular network originated from prosthetic aortic valve area (Fig. 3). A surgical resection was recommended but she preferred another hospital for surgery.

The incidence of primary cardiac tumors ranges from 17 to 2700 per million autopsies. Seventy-five percent of primary cardiac tumors are benign. Approximately 50% of benign cardiac tumors were myxoma. Hemangioma accounts for only 2.8% (1). Echocardiography is a sensitive and noninvasive method for detecting cardiac tumors (2). Although echocardiography can detect tumor and its location, cardiac

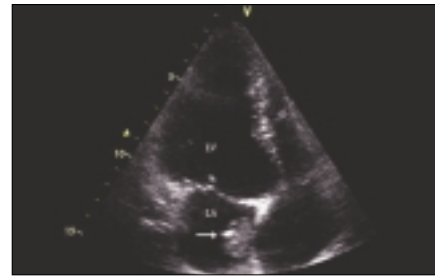


Figure 1. The transthoracic image of left atrial mass
LA- left atrium, LV- left ventricle

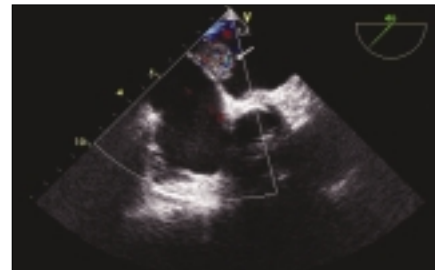


Figure 2. Blood flow within the mass demonstrated using color Doppler transesophageal echocardiography